

CME

ACG Clinical Guideline: Diagnosis and Management of Achalasia

Michael F. Vaezi, MD, PhD, MSc, FACP¹, John E. Pandolfino, MD, MSCI² and Marcelo F. Vela, MD, MSCR³

Achalasia is a primary motor disorder of the esophagus characterized by insufficient lower esophageal sphincter relaxation and loss of esophageal peristalsis. This results in patients' complaints of dysphagia to solids and liquids, regurgitation, and occasional chest pain with or without weight loss. Endoscopic finding of retained saliva with puckered gastroesophageal junction or barium swallow showing dilated esophagus with birds beaking in a symptomatic patient should prompt appropriate diagnostic and therapeutic strategies. In this ACG guideline the authors present an evidence-based approach in patients with achalasia based on a comprehensive review of the pertinent evidence and examination of relevant published data.

Am J Gastroenterol 2013; 108:1238–1249; doi:10.1038/ajg.2013.196; published online 23 July 2013

In the development of this ACG Guideline, the central themes examined included definition, diagnosis, and current therapeutic options for patients with achalasia by interaction between the authors of the technical review and the ACG Practice Parameters Committee. Recommendations were made based on a comprehensive review of the pertinent evidence and examination of quality and relevant published data in the literature.

A search of MEDLINE via PubMed was made using the terms “achalasia” and limited to “clinical trials” and “reviews” for years 1970–2012, and language restriction to English was made for preparation of this document. The resultant conclusions were based on the best available evidence or, in the absence of quality evidence, expert opinion. The GRADE (Grading of Recommendations Assessment, Development, and Evaluation) system was used to grade the quality of evidence and strength of recommendations (**Table 1**) (1). The quality of evidence ranges from “high” (further research is very unlikely to change our confidence in the estimate of effect) to “moderate” (further research is likely to have an important impact on our confidence in the estimate of effect and may change the estimate) to “low” (further research is very likely to have important impact on our confidence in the estimate of effect and is likely to change the estimate), and “very low” (any estimate of effect is very uncertain). The strength of a recommendation is graded as strong when the desirable effects of an intervention clearly outweigh the undesirable effects and is graded as weak when uncertainty exists regarding the tradeoffs (**Table 1**).

DEFINITION AND EPIDEMIOLOGY OF ACHALASIA

Recommendation

1. Achalasia must be suspected in those with dysphagia to solids and liquids and in those with regurgitation unresponsive to an adequate trial of proton pump inhibitor (PPI) therapy (strong recommendation, low-quality evidence).

Achalasia is a primary esophageal motor disorder of unknown etiology characterized *manometrically* by insufficient relaxation of the lower esophageal sphincter (LES) and loss of esophageal peristalsis; *radiographically* by aperistalsis, esophageal dilation, with minimal LES opening, “bird-beak” appearance, poor emptying of barium; and *endoscopically* by dilated esophagus with retained saliva, liquid, and undigested food particles in the absence of mucosal stricturing or tumor.

Achalasia is an uncommon but quintessential esophageal motility disorder defined traditionally by manometric criteria in the classic setting of dysphagia (2–6). It is an incurable disease characterized by incomplete or absent relaxation of the LES and aperistalsis of the esophageal body. The symptomatic consequence of this motility disorder is the classic presentation of dysphagia to solids and liquids associated with regurgitation of bland undigested food or saliva (2). Substernal chest pain during meals in the setting of dysphagia, weight loss, and even heartburn may be accompanying symptoms that often lead to misdiagnosis of achalasia erroneously as gastroesophageal reflux disease (GERD) (7,8). Achalasia must be suspected in those with

¹Division of Gastroenterology, Hepatology and Nutrition, Vanderbilt University Medical Center, Nashville, Tennessee, USA; ²Department of Gastroenterology and Hepatology, Northwestern University, Chicago, Illinois, USA; ³Division of Gastroenterology and Hepatology, Baylor College of Medicine and Michael E. DeBakey VA Medical Center, Houston, Texas, USA. **Correspondence:** Michael F. Vaezi, MD, PhD, MSc, FACP, Division of Gastroenterology, Hepatology and Nutrition, Vanderbilt University Medical Center, 1660 TVC, 1301–22nd Avenue South, Nashville, Tennessee 37232-5280, USA. E-mail: Michael.vaezi@vanderbilt.edu
Received 3 July 2012; accepted 1 May 2013

Table 1. The GRADE (Grading of Recommendations Assessment, Development, and Evaluation) system for grading evidence and strength of recommendations

<i>Strength of recommendations</i>
<i>Strong:</i> The desirable effects of an intervention clearly outweigh the undesirable effects or clearly do not.
<i>Weak:</i> The tradeoffs are less certain between the desirable and undesirable effects of an intervention.
<i>Quality of evidence</i>
<i>High:</i> Further research is very unlikely to change our confidence in the estimate of effect.
<i>Moderate:</i> Further research is likely to have an important impact on our confidence in the estimate of effect and may change the estimate.
<i>Low:</i> Further research is very likely to have an important impact on our confidence in the estimate of effect and is likely to change the estimate.
<i>Very low:</i> Any estimate of effect is very uncertain.

dysphagia to solids and liquids and in those with regurgitation unresponsive to an adequate trial of PPI therapy. Although there is no standardized definition of what an adequate trial of PPI constitutes in this context, recent GERD guidelines suggest that before a diagnostic workup in patients with refractory symptoms, PPI therapy should be optimized by confirmation of compliance, possibly changing to a different PPI, and eventually a trial of b.i.d. dosing (9). Endoscopic findings of retained saliva, liquid, and food in the esophagus without mechanical obstruction from stricture or mass should raise suspicion for achalasia. Conversely, other conditions may mimic achalasia both clinically and manometrically. These include pseudoachalasia from tumors in the gastric cardia or those infiltrating the myenteric plexus (adenocarcinoma of gastroesophageal junction, pancreatic, breast, lung, or hepatocellular cancers) or secondary achalasia from extrinsic processes such as prior tight fundoplication or laparoscopic adjustable gastric banding (10,11). In these cases, clinical history of significant acute weight loss should alert the clinician for the former and a history of surgical intervention to the latter diagnoses. Infection by *Trypanosoma cruzi*, also known as Chagas disease, can also result in achalasia (12). Patients with this disease often have other features of diffuse enteric myenteric destruction, including megacolon, heart disease, and neurologic disorders.

Achalasia occurs equally in men and women with an incidence of 1 in 100,000 individuals annually and prevalence of 10 in 100,000 (2,3). There is no racial predilection. The peak incidence occurs between 30 and 60 years of age. The etiology is autoimmune, viral immune, or neurodegenerative (2,3). The pathologic consequence of the disease is degeneration of ganglion cells in the myenteric plexus of the esophageal body and the LES. Although the cause for the degenerative processes is unclear, the end result of the inflammatory process is loss of inhibitory neurotransmitters nitrous oxide and vasoactive intestinal peptide and consequently imbalance between the excitatory and inhibitory neurons. This results in unopposed

cholinergic activity that leads to incomplete relaxation of the LES and aperistalsis due to loss of latency gradient along the esophageal body.

DIAGNOSIS OF ACHALASIA

Recommendations

1. All patients with suspected achalasia who do not have evidence of a mechanical obstruction on endoscopy or esophagram should undergo esophageal motility testing before a diagnosis of achalasia can be confirmed (strong recommendation, low-quality evidence).
2. The diagnosis of achalasia is supported by esophagram findings including dilation of the esophagus, a narrow esophagogastric junction with “bird-beak” appearance, aperistalsis, and poor emptying of barium (strong recommendation, moderate-quality evidence).
3. Barium esophagram is recommended to assess esophageal emptying and esophagogastric junction morphology in those with equivocal motility testing (strong recommendation, low-quality evidence).
4. Endoscopic assessment of the gastroesophageal junction and gastric cardia is recommended in all patients with achalasia to rule out pseudoachalasia (strong recommendation, moderate-quality evidence).

Esophageal manometry

By definition, an assessment of esophageal motor function is essential in the diagnosis of achalasia. Barium esophagram and esophagogastroduodenoscopy (EGD) are complementary tests to manometry in the diagnosis and management of achalasia. However, neither EGD nor barium esophagram alone is sensitive enough to make the diagnosis of achalasia with certainty. EGD may be supportive of a diagnosis of achalasia in only one-third of patients, whereas esophagram may be nondiagnostic in up to one-third of patients (13). Thus, “normal” findings on EGD or esophagram in patients suspected of having achalasia should prompt esophageal motility testing. However, in patients with classic endoscopic and/or esophagram findings, esophageal motility would be considered supportive to confirm the diagnosis.

The manometric finding of aperistalsis and incomplete LES relaxation without evidence of a mechanical obstruction solidifies the diagnosis of achalasia in the appropriate setting (14) (Table 2 and Figure 1). Other findings, such as an increased basal LES pressure, an elevated baseline esophageal body pressure, and simultaneous non-propagating contractions, may also support the diagnosis of achalasia, but these are not requirements for the diagnosis (6). Variants of achalasia with differing degrees of incomplete LES relaxation and aperistalsis as well as some with complete LES relaxation are rare but have also been described (15–18). Aperistalsis defined as a lack of esophageal body propagating contractile activity can present with different pressure patterns, such as a quiescent esophageal body, isobaric pan-esophageal pressurization, and simultaneous contractions (19). Some have also described

Table 2. Comparison of manometric abnormalities in conventional and high-resolution manometry

Manometric features of achalasia	Conventional manometry Line tracing format	High-resolution manometry Esophageal pressure topography
LES	<p><i>Impaired LES relaxation^a</i></p> <ul style="list-style-type: none"> • Mean swallow induced fall in resting LES pressure to a nadir value of >8 mm Hg above gastric pressure • Complete relaxation to gastric baseline with a short duration (<6s)^b <p><i>Basal pressure^b</i></p> <ul style="list-style-type: none"> • >45 mmHg 	<p><i>Impaired EGJ relaxation</i></p> <ul style="list-style-type: none"> • Mean 4s IRP ≥ 10 mm Hg over test swallows^a
Esophageal peristalsis	<p><i>Aperistalsis in distal 2/3 of the esophagus</i></p> <ul style="list-style-type: none"> • No apparent contractions • Simultaneous contractions with amplitudes <40 mmHg 	<p><i>Aperistalsis</i></p> <ul style="list-style-type: none"> • Absent peristalsis (type I) • Pan-esophageal pressurization (type II)
Atypical/variants	<p><i>Vigorous</i></p> <ul style="list-style-type: none"> • Preserved peristalsis with esophageal contractions >40 mmHg • Simultaneous contractions >40 mmHg <ul style="list-style-type: none"> -Isobaric -Nonisobaric 	<ul style="list-style-type: none"> • Spastic achalasia (type III)

EGJ, esophagogastric junction; IRP, integrated relaxation pressure; LES, lower esophageal sphincter.

^aRequired for diagnosis.

^bSupportive for the diagnosis.

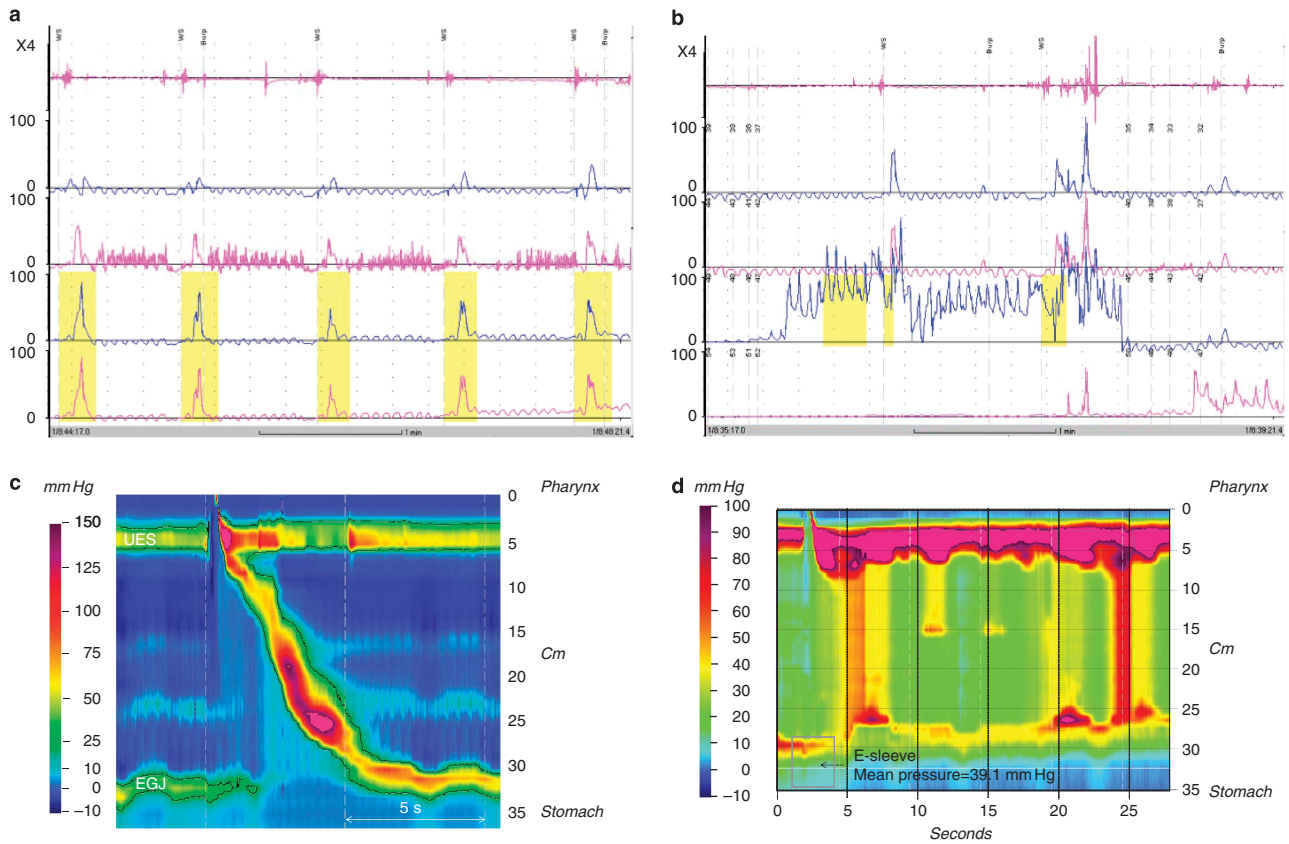


Figure 1. Manometric tracings of normal and achalasia. (a) Simultaneous esophageal contractions associated with high lower esophageal sphincter (LES) pressure and (b) incomplete relaxation noted during conventional water-perfused manometry. High-resolution manometry (HRM) tracings of (c) normal esophageal peristalsis and (d) achalasia showing simultaneous contractions along the esophagus with high E-sleeve LES pressure and incomplete relaxation. EGJ, esophagogastric junction; UES, upper esophageal sphincter.

achalasia variants presenting with propagating contractions that could represent either early achalasia or most commonly a sub-clinical mechanical obstruction at the esophagogastric junction (EGJ) (18,20). This heterogeneity also strengthens the requirement that motor patterns be defined as this may affect diagnosis and management.

The manometric techniques and equipment available in clinical practice range from conventional catheters with pressure sensors spaced anywhere from 3 to 5 cm apart utilizing solid-state technology or a water-perfused extrusion catheter to high-resolution manometry (HRM) assemblies that incorporate pressure sensors at 1 cm intervals with either a water-perfused extrusion or various solid-state technologies. Any of the current manometric systems can be utilized to evaluate LES relaxation with the caveat that the pressure measurements need to account for LES movement secondary to deglutitive longitudinal muscle shortening. Thus, a measurement domain extending above and below the EGJ is the preferred technique for measuring deglutitive LES relaxation pressure and this can be accomplished with either a water-perfused Dent sleeve (21) or an electronic sleeve derived from high-resolution sensors through the EGJ (22). Standard measurements of LES function, such as basal end-expiratory LES pressure, nadir LES relaxation pressure, and percent relaxation, are accurately measured with these tools. Data are emerging to suggest that HRM may have increased sensitivity in diagnosing achalasia than the conventional manometry techniques (23); however, future clinical studies are needed to confirm this assertion.

Conventional manometric techniques and the utilization of tracing analysis with spaced intervals from 3 to 5 cm can be utilized to depict the pressure profile through the smooth muscle esophagus; however, new space-time analysis paradigms with HRM may prove useful in not only diagnosis but also predicting treatment response in achalasia. Utilizing interpolation techniques to bridge the pressure sensors in HRM, Clouse and Staiano (24,25) created an analysis paradigm that portrays the pressure signal through the esophagus in a seamless dynamic space-time continuum in the form of esophageal pressure topography. This analysis technique merged anatomy with pressure mechanics and provided improved accuracy in identifying landmarks and distinguishing pressure patterns. Esophageal pressure topography has allowed for the differentiation of achalasia into three subtypes (**Table 2**) or variants (19) with potential treatment outcome implications. To date, three separate retrospective cohort studies have shown that subtype II has the best prognosis, whereas subtype I is somewhat lower and subtype III can be difficult to treat (19,26,27). Although these subtypes can be defined with careful analysis of conventional tracings, it is easier and more reproducible with HRM. Future outcome studies are needed to determine the clinical impact of the three subtypes.

Contrast studies

The diagnosis of achalasia is supported by esophagram findings including dilation of the esophagus, a narrow EGJ with “bird-beak” appearance, aperistalsis, and poor emptying of barium.

It may also be helpful in cases where esophageal manometry may be associated with equivocal findings. In addition to supporting the diagnosis of achalasia, an esophagram is also useful to assess for late- or end-stage achalasia changes (tortuosity, angulation, megaesophagus) that have implications for treatment.

An additional role for radiological examination is to provide objective assessment of esophageal emptying after therapy. In many patients with achalasia, symptom relief does not always parallel esophageal emptying. This was initially demonstrated by measuring barium column height 1 and 5 min after upright ingestion of a large barium bolus; an approach that has come to be known as the “timed barium esophagram” (TBE) (28). Subsequent data (discussed in the “follow-up” section) suggested (29–31) usefulness of TBE for the objective evaluation of achalasia patients after treatment, as it helps identify patients who are more likely to fail treatment despite initial symptomatic improvement.

Endoscopy

The primary role of EGD in the workup of achalasia is focused on ruling out a mechanical obstruction or pseudoachalasia as they can mimic achalasia both clinically and manometrically (10,32,33). Similar to the manometric features in achalasia, mechanical obstruction can result in both impaired EGJ relaxation and abnormal esophageal body function (aperistalsis or spastic contractions) (20). Clinical presentation of dysphagia to solids and liquids in association with older age, weight loss, and a short duration of symptoms may clinically be suggestive of an infiltrating cancer; however, they are not sensitive or specific (34). Thus, patients presenting with a motor pattern or esophagram consistent with achalasia should be referred for endoscopic assessment with careful evaluation of the EGJ and gastric cardia on retroflexed view to rule out an infiltrating cancer.

Endoscopic evaluation can also be useful in raising initial suspicion for the diagnosis of achalasia in patients erroneously diagnosed with GERD. In this group, endoscopic findings of a dilated esophagus with retained food or saliva and a puckered gastroesophageal junction are helpful in establishing the correct diagnosis. Endoscopic findings in achalasia may range from a seemingly normal examination to a tortuous dilated sigmoid esophagus with retained food and secretions. Thus, endoscopy may not be sensitive in those with a nondilated esophagus, and esophageal motility test is indicated if there is clinical suspicion for achalasia. Endoscopic mucosa in achalasia may be normal; however, as it becomes dilated, it is not uncommon to find inflammatory changes or ulcerations secondary to stasis, pill esophagitis, or candida infection. Although esophageal biopsies are generally recommended in patients undergoing endoscopy for dysphagia to rule out eosinophilic esophagitis, biopsies are generally not needed if the findings on endoscopy are consistent with achalasia. However, it is not uncommon to find an increased number of eosinophils in patients with achalasia secondary to the primary inflammatory process leading to loss of ganglion cells or potentially a secondary inflammatory process related to stasis inflammation (35,36). Distinguishing eosinophilic esophagitis may be difficult as evidenced by a recent case report of a patient with achalasia and dense eosinophilic infiltrate responding to cor-

ticosteroids (37); however, the clinical presentation of dysphagia to solids and liquids and the classic manometric findings in achalasia help distinguish the two diagnoses.

The endoscopic findings at the EGJ in achalasia may also range from normal-appearing to a thickened muscular ring that may have a rosette configuration on retroflexion view. Intubation of the stomach through the EGJ may be associated with mild resistance; however, stronger resistance should prompt an evaluation for pseudoachalasia with further imaging. Endoscopic ultrasound may be helpful in this scenario and it is also valuable in evaluating patients with a variant presentation on manometry associated with propagating contractile activity (38). This technique can rule out infiltrating tumor and also provide supportive evidence of achalasia in the context of documenting a thickened circular muscle layer at the LES and through the smooth muscle esophagus (39). Endoscopic ultrasound should be performed in patients in whom there is a strong suspicion for malignancy. This group could include elderly patients with short history of dysphagia but marked weight loss or in those where endoscopic evaluation is atypical (unusual increased resistance to passage of scope or mucosal changes).

In summary, for achalasia diagnosis, esophageal motility testing, EGD, and barium esophagram play complementary roles. Whereas EGD is essential to rule out pseudoachalasia, esophageal motility testing and barium esophagram may play confirmatory roles. In those with classic motility findings, barium esophagram may be redundant. Similarly, in those with classic barium esophagram findings, esophageal motility testing serves only to confirm the suspicion for achalasia. It is in those with equivocal motility findings where barium esophagram is essential to assess for retention of barium and confirm the diagnosis.

TAILORED APPROACH TO TREATING ACHALASIA

Recommendations

1. Either graded pneumatic dilation (PD) or laparoscopic surgical myotomy with a partial fundoplication are recommended as initial therapy for the treatment of achalasia in those fit and willing to undergo surgery (strong recommendation, moderate-quality evidence).
2. PD and surgical myotomy should be performed in high-volume centers of excellence (strong recommendation, low-quality evidence).
3. The choice of initial therapy should be guided by patients' age, gender, preference, and local institutional expertise (weak recommendation, low-quality evidence).
4. Botulinum toxin therapy is recommended in patients who are not good candidates for more definitive therapy with PD or surgical myotomy (strong recommendation, moderate-quality evidence).
5. Pharmacologic therapy for achalasia is recommended for patients who are unwilling or cannot undergo definitive treatment with either PD or surgical myotomy and have failed botulinum toxin therapy (strong recommendation, low-quality evidence).

Achalasia is a chronic condition without cure. Current treatments options in achalasia are aimed at reducing the hypertonicity of the LES by pharmacologic, endoscopic, or surgical means. No intervention significantly affects esophageal peristalsis, and despite therapeutic interventions the LES hypertonicity returns over time, requiring repeat interventions. The goals in treating achalasia are to relieve patients' symptoms, improve esophageal emptying, and prevent further dilation of the esophagus. To achieve these goals, the available therapeutic option must be tailored to patients with achalasia.

Pharmacologic therapy

Oral pharmacologic therapies are the least effective treatment options in achalasia (40). Calcium channel blockers and long-acting nitrates are the two most common medications used to treat achalasia. They transiently reduce LES pressure by smooth muscle relaxation, facilitating esophageal emptying. The phosphodiesterase-5-inhibitor, sildenafil, has also been shown to lower the LES tone and residual pressure in patients with achalasia (41). Other less commonly used medications include anticholinergics (atropine, dicyclomine, cimetropium bromide), β -adrenergic agonists (terbutaline), and theophylline. Overall, calcium channel blockers decrease LES pressure by 13–49% and improve patient symptoms by 0–75%. The most commonly employed calcium channel blocker is nifedipine, showing time to maximum effect after ingestion of 20–45 min with duration of effect ranging from 30 to 120 min. Thus, it should be used (10–30 mg) sublingually 30–45 min before meals for best response. Sublingual isosorbide dinitrate is also effective in decreasing LES pressure by 30–65%, resulting in symptomatic improvement ranging from 53 to 87%. It has a shorter time to maximum reduction in LES pressure (3–27 min) than sublingual nifedipine but also has a shorter duration of effect (30–90 min). Hence, sublingual isosorbide dinitrate (5 mg) is commonly administered only 10–15 min before meals. The only comparative study of sublingual nifedipine to sublingual isosorbide dinitrate showed a nonsignificant edge in LES pressure reduction with the latter (65%) than the former (49%) (42). The clinical response with pharmacologic agents is short acting and the side effects, such as headache, hypotension, and pedal edema, are common limiting factors in their use. Furthermore, they do not provide complete relief of symptoms. Thus, these agents are commonly reserved for patients with achalasia who cannot or refuse to undergo more definitive therapies (PD or surgical myotomy) and those who have failed botulinum toxin injections.

Pharmacologic therapy via endoscopy. Botulinum toxin (Botox) is a potent presynaptic inhibitor of acetylcholine release from nerve endings that has proven to be a useful treatment in achalasia (43). The toxin cleaves the protein (SNAP-25) involved in fusing presynaptic vesicles containing acetylcholine with the neuronal plasma membrane in contact with the target muscle. This, in turn, inhibits exocytosis of acetylcholine into the synaptic area and causes a short-term paralysis of the muscle by blocking the unopposed cholinergic stimulation of the LES, which is devoid of inhibitory influence in achalasia. This effect interrupts the neuro-

genic component of the sphincter; however, it has no effect on the myogenic influence maintaining basal LES tone. Thus, the treatment is limited and most treatment effects are associated with an ~50% reduction in the basal LES pressure (44). This reduction may be sufficient to allow esophageal emptying when esophageal pressure rises to a level where it can overwhelm the partially paralyzed LES.

The main appeal of botulinum toxin treatment is the user-friendly approach that is not much more complicated than performing elective endoscopy and the low rates of serious complications. The standard approach is to place 100 units of the toxin using a scleroneedle just above the squamocolumnar junction in at least 4 quadrants. The toxin is usually diluted in preservative-free saline and injected in 0.5–1 ml aliquots. Doses higher than 100 units have not been shown to be more effective (45) and the 12-month success rate ranges from 35 to 41%. Although the initial (one-month) response rate is high (>75%), the therapeutic effect eventually wears off and repeat injection is often required in a significant portion of the patients. Approximately 50% of patients relapse and require repeat treatments at 6–24-month intervals (45–48). Features associated with prolonged response are older age and a manometric pattern described as vigorous (49); however, this may be more akin to the type II pattern associated with pan-esophageal pressurization by HRM (19). Serious side effects are uncommon and the main treatment-specific issues are related to a 16–25% rate of developing chest pain and rare complications, such as mediastinitis and allergic reactions related to egg protein. In addition, multiple treatments can create an inflammatory reaction that may obscure the mucosal–muscle plane associated with a higher rate of surgical complications (50–52). In addition, there is some evidence that injection of botulinum toxin into the LES may increase the difficulty in subsequent surgical myotomy (52). Given these limitations, the utilization of botulinum toxin is restricted to specific circumstances where PD and surgical myotomy are not considered appropriate because of inherent patient-related risks. Alternatively, botulinum toxin can be considered as an adjunct treatment in patients with residual spastic contractions above the myotomy site or LES; however, outcome-related data are lacking.

Pneumatic dilation

PD is the most effective nonsurgical option for patients with achalasia (2). Bougienage or standard balloon dilations are not effective in fracturing the muscularis propria needed for symptomatic relief in this group of patients. All patients considered for PD must also be candidates for surgical intervention in the event of esophageal perforation needing repair. PD uses air pressures to intraluminally dilate and disrupt the circular muscle fibers of the LES. Today, the most commonly employed balloon dilator for achalasia is the nonradiopaque graded size polyethylene balloons (Rigiflex dilators). The procedure is always performed under sedation and traditionally under fluoroscopy, although data suggest that direct endoscopic-guided balloon positioning may also be employed (53,54). The dilators come in three different disposable balloon diameters (3.0, 3.5, and 4.0 cm). In comparison, the largest standard through-the-scope balloons employed

have a diameter size of 2.0 cm, which explains their lack of clinical effectiveness and inability to cause LES disruption. The most important aspects of PD are expertise of the operator and the presence of institutional backup for surgical intervention in case of perforation (55). Accurate positioning of the Rigiflex balloon across the LES is important in its effectiveness. Balloon distention to the maximum diameter endoscopically or by obliteration of the balloon waist during fluoroscopy is important in clinical effectiveness of the procedure rather than the balloon distention time. The pressure required is usually 8–15 psi of air held for 15–60 s. After dilation, all patients must undergo radiographic testing by gastrograffin study followed by barium esophagram to exclude esophageal perforation (56). PD is performed as an outpatient procedure and patients can be discharged after dilation. Patients should be instructed to seek immediate attention if they develop severe chest pain with or without fever after discharge as delayed perforation because of vomiting after procedure is possible.

Studies suggest that by using the graded dilator approach, good-to-excellent relief of symptoms is possible in 50–93% of patients (2,40,57,58). Cumulatively, dilation with 3.0, 3.5, and 4.0 cm balloon diameters results in good-to-excellent symptomatic relief in 74, 86, and 90% of patients with an average follow-up of 1.6 years (range 0.1–6 years). Furthermore, the rate of perforation may be lower with the serial balloon dilation approach. Initial dilation using a 3-cm balloon is recommended for most patients followed by symptomatic and objective assessment in 4–6 weeks. If patients continue to be symptomatic, the next size dilator may be employed. A small randomized trial of first PD comparing balloon size of 3.0 vs. 3.5 cm and inflation time of 15–60 s showed that the more conservative 3.0 cm balloon inflated for just 15 s delivered symptom response equal to the more aggressive approach of the larger dilator inflated over longer duration (59). The success of single PD was reported at 62% at 6 months and 28% at 6 years, whereas serial dilation resulted in symptom improvement in 90% of patients at 6 months and 44% at 6 years (57). In a European retrospective study in which serial dilation was performed with the goal of reducing the LES pressure below 15 mm Hg, a 3-year success of 78–85% was reported with PD (60). Overall, a third of treated patients will experience symptom relapse over 4–6 years of follow-up. Predictors of favorable clinical response to PD include: older age (>45 years), female gender (61), narrow esophagus predilation, LES pressure after dilation of <10 mm Hg (62), and type II pattern on HRM (19,63). The serial approach in PD may not be as effective in younger males (age <45 years), possibly because of thicker LES musculature. In this group, it is recommended that the PD employing the 3.5 cm balloon or surgical myotomy may be the best initial approach.

The most serious complication associated with PD is esophageal perforation with an overall median rate in experienced hands of 1.9% (range 0–16%) (57,64). Every patient undergoing PD must be aware of the risk and understand that surgical intervention is likely as a result of perforation. Early recognition and management of perforation is key to better patient outcome. There are no predilation predictors of perforation; however, most perforations

happen during the first dilation possibly because of inappropriate positioning and distention of the balloon. Conservative therapy with antibiotic, parenteral nutrition, and stent placement may be effective in small perforation, but surgical repair through thoracotomy is the best approach in large and extensive mediastinal contamination. GERD may occur after PD in 15–35% of patients and recurrence of dysphagia should exclude GERD-related distal esophageal stricture as a potential contributing complication. Thus, PPI therapy is indicated in those with GERD after PD. PD may also be employed in those who failed myotomy, but this group does not do well with dilation unless they have a higher resting LES pressure (65).

Surgical myotomy

The original approach to surgical myotomy involved division of the muscle fibers of the LES (circular layer without disruption of the mucosa) through a thoracotomy (66). This achieved good-to-excellent results in 60–94% of patients followed for 1–36 years (40), and it remained the surgery of choice for many years. The technique evolved initially with a laparotomy approach, which was subsequently supplanted by minimally invasive techniques. A thoracoscopic approach was developed and used with success, but laparoscopic myotomy has become the preferred method because of decreased morbidity and faster recovery (66).

Studies comparing the effectiveness of surgical modalities in achalasia are not homogeneous in follow-up length and definition of treatment success (58). Furthermore, all of the available literature is based on prospective or retrospective cohort case/control studies, as there are no randomized control trials comparing the different approaches to myotomy. In 13 studies of open transthoracic myotomy that included a total of 842 patients, symptom improvement was achieved in a mean 83% of patients (range 64–97%). For open transabdominal myotomy, symptom improvement was achieved in 85% (range 48–100%) of 732 patients in 10 studies. Data for thoracoscopic myotomy included 211 patients from 8 studies, with symptom improvement in a mean 78% (range 31–94%) of patients. Finally, in 39 studies of laparoscopic myotomy that included a total of 3,086 patients, symptom improvement was achieved in a mean 89% of patients (range 77–100%) (58). As with PD, the efficacy of Heller myotomy decreases with longer follow up-periods. In a series of 73 patients treated with Heller myotomy, excellent/good responses were reported in 89% and 57% of patients at 6 months and 6 years of follow-up, respectively (57). In addition, some have suggested that prior PD may result in a higher rate of intraoperative mucosal perforation but no change in the long-term symptomatic outcome (67).

The development of GERD after myotomy is a frequent problem and whether an antireflux procedure should be performed to prevent reflux has been the subject of extensive debate, especially given concerns for increased postoperative dysphagia after a fundoplication. The average frequencies of GERD after surgical myotomy without fundoplication for thoracotomy, laparotomy, thoracoscopy, and laparoscopy are similar: 29%, 28%, 28%, and 31% respectively (58). Adding fundoplication after myotomy decreases the risk of GERD for thoracotomy, laparotomy, and

laparoscopy; 14%, 8%, and 9%, respectively. No study has included fundoplication after thoracoscopic myotomy (58). The benefit of adding a fundoplication was demonstrated in a double-blind randomized trial comparing myotomy with vs. without fundoplication (68). In this study, abnormal acid exposure on pH monitoring was found in 47% of patients without an antireflux procedure and 9% in patients that had a posterior Dor fundoplication. Furthermore, a subsequent cost–utility analysis based upon the results of this randomized double-blind trial found that myotomy plus Dor fundoplication was more cost effective than myotomy alone because of the costs of treating GERD (69). The most recent achalasia guidelines from the Society of American Gastrointestinal and Endoscopic Surgeons recommended that patients who undergo myotomy should have a fundoplication to prevent reflux (70). Although it has been fairly well established that adding a fundoplication is beneficial for reducing the rate of GERD after myotomy, there is less certainty on the best approach (anterior Dor or posterior Toupet). A recent multicenter randomized controlled trial comparing these two approaches found a nonsignificant higher percentage of abnormal pH test results in 24 patients with Dor compared with 19 patients with Toupet fundoplication (41% vs. 21%), with similar improvement in dysphagia and regurgitation symptoms in both groups (71). The rate of dysphagia appears to be independent of the presence or absence of fundoplication after myotomy (58). *Given the likelihood of reflux symptoms and/or abnormal pH testing after myotomy despite added fundoplication, PPI therapy may be indicated in those who complain of heartburn.*

Esophagectomy

Some patients may develop “end-stage” achalasia characterized by megaesophagus or sigmoid esophagus and significant esophageal dilation and tortuosity. In this group of patients, PD may be less effective but a surgical myotomy may be a reasonable initial approach before consideration for esophagectomy. Two recent studies documented symptomatic improvement after myotomy in 92% (72) and 72% (73) of patients with megaesophagus. However, in those unresponsive to therapy, esophageal resection is frequently required (74). Esophagectomy is associated with a greater morbidity/mortality than laparoscopic Heller myotomy, and should be reserved for patients who have failed PD and/or myotomy and who are good candidates for surgery. Dysphagia requiring dilation may occur in up to 50% of patients after esophagectomy (75). Data from uncontrolled studies show generally good response to esophagectomy, with symptom improvement in over 80% of patients with end-stage achalasia; mortality ranges between 0 and 5.4% (76). There is a paucity of studies comparing the two main approaches to esophagectomy, that is, gastric or colonic interposition. However, a recent extensive review on this topic found that gastric interposition is the first choice of therapy in the majority of patients undergoing esophagectomy (77).

Comparative effectiveness of therapeutic modalities

PD vs. botox. These treatment approaches have been compared in randomized controlled trials. For instance, a study of 42 patients who were randomized to botox injection or graded PD with 30

and 35 mm Rigiflex balloons reported success of 70% for PD and 32% for botox at 12 months (46). A recent Cochrane database review of 6 studies involving 178 patients found no significant difference in remission between PD and botox treatment within 4 weeks of the initial intervention (78). Three studies included in the review had 12-month data with remission in 33 of 47 PD patients compared with 11 of 43 botox patients (relative risk of 2.67, 95% confidence interval 1.58–4.52). These results provide strong evidence that PD is more effective than botox in the long term for patients with achalasia.

PD vs. Heller myotomy. A recent systematic review compared the effectiveness of laparoscopic myotomy in 3,086 patients and PD in 1,065 patients, showing that symptom relief was significantly higher for laparoscopic myotomy combined with an antireflux procedure compared with PD at both 12 months (89.3% vs. 68.2%) and >36 months after treatment (89.3% vs. 56.3%) (58). In this study, myotomy outcome was compared with the result of first PD, with repeat PD being considered failure to therapy. This is not consistent with the accepted clinical approach of graded PD with repeat treatment as needed (5). In the only prospective randomized multicenter European trial comparing the two modalities, 200 achalasia patients were randomized to laparoscopic myotomy with Dor fundoplication or PD, allowing for a maximum of three series of dilations in the PD group. There was no difference in success rates after 2 years of follow-up: 92% for PD vs. 87% for laparoscopic myotomy (79). Thus, based on this evidence, laparoscopic myotomy and PD have comparable success rates.

Comparative cost of different achalasia treatments. Two early studies compared the costs of Heller myotomy, PD, and botulinum toxin injection. A cost minimization study from the year 2000 found that the costs per symptomatic cure over a 10-year horizon were \$10,792 for Heller myotomy, \$3,723 for botulinum injection, and \$3,111 for PD (80). A 2002 cost-effectiveness study that accounted for quality of life over a 5-year horizon determined the costs of botulinum injection, PD, and Heller myotomy to be \$7,011, \$7,069, and \$21,407, respectively. Although the cost of botulinum toxin injection was slightly lower, PD was more cost effective, with an incremental cost effectiveness of \$1,348 per quality-adjusted life year (81). More recently, a 2007 decision analytic model demonstrated that laparoscopic myotomy is more costly than PD in all tested scenarios; the expected cost per patient was \$10,789 for myotomy compared with \$5,315 for PD at 5 years after diagnosis. This cost differential persisted even after 10 years, with myotomy costing \$11,804 compared with \$7,717 for PD (82). A 2007 randomized clinical trial also showed the superior cost effectiveness of PD over myotomy (83). Thus, PD is consistently shown to be the most cost-effective treatment option for achalasia.

Emerging therapies

Although the current treatments for achalasia are effective, PD is associated with a perforation risk of 1.9% (84), and myotomy still

requires laparoscopy and dissection of the EGJ. Thus, there has been interest in developing hybrid techniques that incorporate an endoscopic approach with principles of NOTES (natural orifice transluminal endoscopic surgery) to perform a myotomy. This technique was developed in Japan and is termed POEM (peroral esophageal myotomy)(85). The procedure requires the creation of a submucosal plane using a forward-viewing endoscope with a distal transparent cap to access the circular muscle fibers for performance of the myotomy. An endoscopic submucosal dissection knife is used to dissect the plane and also cut the muscle over a minimum length of 6 cm into the esophagus and 2 cm below the squamocolumnar junction onto the cardia. Overall, the success rate, defined by an improvement in symptoms and no requirement of additional medical or surgical treatment, in prospective cohorts have been >90% (86–88), and this does appear to have promise as an alternative to the laparoscopic approach. Randomized prospective comparison trials with standard laparoscopic myotomy and/or PD are needed and POEM should only be performed in the context of clinical trials with the understanding that other effective well-studied alternatives are available.

A natural evolution of endoscopic technique for the treatment of achalasia would logically lead to the creation of a stent that could be placed across the EGJ to maintain patency without developing severe reflux. Recently, a prospective randomized study of 120 patients evaluating the long-term efficacy of a special design partially covered removable metallic stent vs. PD was reported from the People's Republic of China. The dilation protocol was much less aggressive than the standard technique used in the United States and Europe as the maximal diameter used was 32 mm. These results revealed that the 30 mm stent had an 83% success rate at 10 years, whereas the success rate for the 20 mm stent and dilation protocol was 0% (89). Although these results appear to be promising, this technique cannot currently be recommended as a treatment in the United States as this represents a single-center experience with a non-FDA-approved device.

PATIENT FOLLOW-UP

Recommendations

1. Patient follow-up after therapy may include assessment of both symptom relief and esophageal emptying by barium esophagram (strong recommendation, low-quality evidence).
2. Surveillance endoscopy for esophageal cancer is not recommended (strong recommendation, low-quality evidence).

Short term

The goals for the management of achalasia are focused on treatment of impaired esophageal emptying as there is no treatment to restore normal smooth muscle function. The treatment goal is therefore focused on improving esophageal emptying through a reduction in the relative obstruction at the EGJ. This will not only improve the symptoms of dysphagia, regurgitation, and aspiration, and less reliably chest pain, but will also reduce the

long-term risks of developing megaesophagus with a potential requirement of esophagectomy. In order to ensure these goals, patients who undergo treatment for achalasia should have a short-term follow-up to gauge success of the intervention and to determine whether further treatments are required. Unfortunately, patient's symptoms or physician impression of treatment success may not be a reliable predictor of outcome as it is confounded by inherent bias. Furthermore, symptom resolution may occur without a significant improvement in esophageal emptying, placing the patient at risk for developing long-term complications of achalasia (29). Thus, functional testing after intervention is preferred over only symptom assessment.

As the primary goals of treating achalasia focus on improving esophageal emptying and improving and disrupting the LES to reduce obstruction at the EGJ, it is logical that contrast studies and manometry figure prominently in the postintervention follow-up. The TBE is an important tool in the management of achalasia both before and after intervention (29). Multiple studies have shown that the results of a postintervention TBE can predict treatment success and requirement for future interventions. In 1999, Vaezi *et al.* (29) presented data to support that there was a significant association between the results of the TBE and symptom resolution after PD. More importantly, however, they identified a group of patients who had poor esophageal emptying in the context of almost complete symptom resolution in which TBE predicted treatment failure at 1 year (30). Although the data do not support that an intervention should be performed based solely on the outcome of the TBE, it does support that follow-up should be more aggressive in patients with abnormal barium height at 5 min regardless of symptoms as they may be at risk of symptomatic relapse. It is thus reasonable to repeat this test annually to assess for esophageal emptying.

Given that the diagnosis of achalasia is heavily dependent on the manometric description of LES function, it is not surprising that postintervention LES function on manometry has been shown to be predictive of treatment outcome. Studies support that a postdilation LES pressure of 10 mm Hg is associated with a higher rate of remission. A prospective study assessing 54 patients followed found that patients with a low posttreatment basal LES pressure are much more likely to be in remission (100% vs. 23%) at 10 years (62). Whether new variables developed using HRM and esophageal pressure topography can better predict outcome than conventional assessment of posttreatment LES pressure or TBE is unclear. In addition, there are no other validated measures or techniques that figure into the postintervention evaluation, and currently one should proceed with either a TBE or a manometric evaluation of basal LES pressure. The choice between these two modalities is related to patient tolerance and sensitivities to radiation exposure as well as expertise within each center.

Long term

In view of the fact that achalasia is not cured by treatment focused at disrupting the LES, patients need to be informed that achalasia

is a chronic disorder that will require long-term (lifelong) follow-up. Even if patients respond to therapy, patients should be advised regarding the risk of end-stage achalasia/megaesophagus and the small but important risk of squamous carcinoma. Thus, a plan for follow-up should be generated for each patient that may be influenced by their current symptom profile and various morphologic features that may predict a poor outcome.

One of the main goals for treating achalasia aggressively is to prevent the formation of megaesophagus, which typically is used to define end-stage achalasia. The definition of end-stage achalasia and megaesophagus is controversial, and currently there are no uniform criteria for this categorization (90,91). Radiologically, severity of achalasia is determined by the degree of dilation and the conformation of the dilated esophagus within the thoracic cavity. Severe achalasia is defined by a diameter > 6 cm (92), whereas others consider the presence of a distal angulation and a sigmoid-like configuration as markers of end-stage achalasia and a doomed myotomy (93,94). These findings are associated with an inability to clear the esophagus despite an adequate myotomy due to a "sinktrap" effect (94) and an inability to generate a permissive pressure gradient.

Approximately 10–15% of patients who have undergone treatment for achalasia will have progressive dilation of the esophageal diameter and will fulfill criteria for megaesophagus or end-stage achalasia (94,95). In addition, up to 5% of patients may require esophagectomy, and patients' reported symptoms do not help predict progression (96). Although it appears logical that aggressive successful treatment of achalasia would reduce the risk of developing end-stage achalasia, there are no data to support a surveillance routine to prevent disease progression. There are also no data to advocate for further treatment of asymptomatic patients despite the presence of predictors of negative outcome, such as an abnormal 5 min timed barium esophagram or an elevated LES pressure > 10 mm Hg.

Management of treatment failures

PD and Heller myotomy have both excellent-to-good efficacy in studies in which patients were followed for up to 2 or 3 years. However, their effectiveness decreases with over time. Although establishing long-term rates of failure may be difficult because of the inherent challenges of following patients for prolonged periods of time, along with differing definitions of failure, the reported rates of retreatment offer a valuable perspective regarding treatment failures. In two recent studies of patients who were followed for a mean 5–6 years after laparoscopic Heller myotomy, 18–21% required additional treatment, most often with PD, but re-do myotomy, botulinum toxin injection, or smooth muscle relaxing medications were also used (97,98). Similarly, in three recent studies of patients who were followed after successful graded PD, 23–35% underwent repeat treatment for symptomatic recurrence during a mean 5–7 years of follow-up, mostly with PD but some patients required surgery (60,97,99). The complexities of managing achalasia, including treatment failures, were shown in a retrospective review of 232 achalasia patients who were followed after therapy for more than a period

of 8 years (95). In this study, 93% of 184 patients did well after initial therapy, especially if combination therapy with more than one modality was employed. However, in those who failed initial myotomy, symptomatic management was more difficult. In this group, the rates of symptom response after PD and repeat myotomy were only 67% and 57%, respectively, with 8 patients eventually requiring esophagectomy. PD after failed myotomy does not appear to increase the risk of perforation, although data regarding this issue are limited (63).

In summary, the efficacy of both PD and Heller myotomy decreases over time. Repeat treatment will be required by a good proportion of patients after 5 years. The choice of therapy to retreat these recurrences has to be individualized according to patient characteristics and available expertise. For these patients, the best chance of success may be through a multidisciplinary team who can offer a multimodality approach that may include botox, PD, re-do myotomy, and, as a last resort, esophagectomy.

Endoscopic surveillance for cancer

The risk of esophageal squamous cell carcinoma is substantially increased in achalasia and the estimated incidence rate is ~1 cancer per 300 patient years, representing a hazard ratio of 28 for developing cancer (100). There has also been evidence that the risk of adenocarcinoma is also increased in achalasia; however, this is substantially lower than the risk for squamous cell carcinoma. The presumed mechanism for cancer in achalasia is focused on poor esophageal emptying and stasis inflammation leading to dysplasia and the development of carcinoma. Despite these risks, there are limited data to support routine screening for cancer. The overall number of cancers remains low and estimates have suggested that over 400 endoscopies would be required to detect one cancer (101). These numbers are further tempered by the fact that the survival of these patients is poor once the diagnosis is made (100). Thus, the latest American Society of Gastrointestinal Endoscopy guidelines report insufficient data to support routine endoscopic surveillance for patients with achalasia (102).

However, there may be additional benefits to surveillance beyond the cancer risk that may make endoscopic surveillance reasonable. For instance, patients with achalasia are still at risk of progression to megaesophagus, and following symptoms may not be sufficient to determine whether patients may be at risk for disease progression. Given these issues and the lack of a good predictive biomarker, many experts are in favor of some form of endoscopic or radiographic surveillance in patients with achalasia if the disease has been present for more than 10–15 years with an interval of every 3 years (103). However, further studies are required to determine whether surveillance strategies with defined intervals or new endoscopic techniques will improve overall outcomes.

TREATMENT ALGORITHM

A reasonable tailored treatment algorithm for patients with achalasia is outlined in **Figure 2**. Symptomatic patients with achalasia

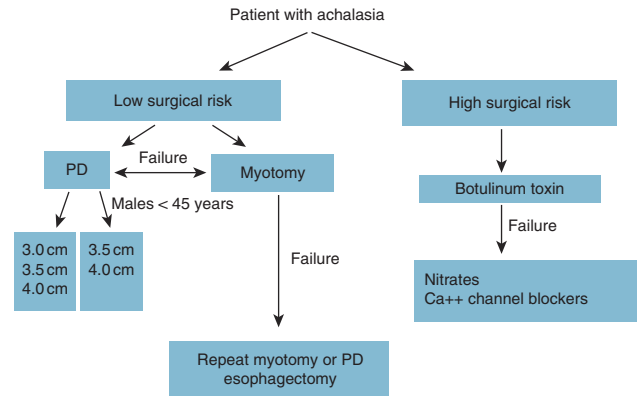


Figure 2. Recommended treatment algorithm for patients with achalasia. PD, pneumatic dilation.

who are good surgical candidates should be offered information about the risks and benefits of the two equally effective treatment options of PD and surgical myotomy. The choice between the procedures should depend on patient preference and institutional expertise. However, to maximize patient outcome, both procedures should be performed in centers of excellence with adequate volume and expertise. PD should be performed in a graded manner, starting with the smallest balloon (3.0 cm), except in younger males (<45 years old) who may benefit with the initial balloon size of 3.5 cm or surgical myotomy. In patients unresponsive to PD, surgical myotomy should be performed. Repeat dilation can be performed in patients with recurrent symptoms after surgical myotomy. Poor surgical candidates should initially undergo injection of the LES with botulinum toxin and should be aware that repeat therapy is often needed. Other medical therapies with nitrates or calcium channel blockers may be offered if there is no clinical response to botulinum toxin injection. Esophagectomy may be needed in those with dilated esophagus (>8 cm) with poor response to an initial myotomy.

CONFLICT OF INTEREST

Guarantor of the article: Michael F. Vaezi, MD, PhD, MSc, FACG.

Specific author contributions: Each author was responsible for sections assigned to them and collectively wrote the manuscript and agreed on the end product.

Financial support: None.

Potential competing interests: None.

REFERENCES

- Guyatt GH, Oxman AD, Vist GE *et al*. GRADE: an emerging consensus on rating quality of evidence and strength of recommendations. *BMJ* 2008;336:924–6.
- Vaezi MF, Richter JE. Diagnosis and management of achalasia. American College of Gastroenterology Practice Parameter Committee. *Am J Gastroenterol* 1999;94:3406–12.
- Francis DL, Katzka DA. Achalasia: update on the disease and its treatment. *Gastroenterology* 2010;139:369–74.
- Eckardt AJ, Eckardt VF. Treatment and surveillance strategies in achalasia: an update. *Nat Rev Gastroenterol Hepatol* 2011;8:311–9.
- Richter JE, Boeckxstaens GE. Management of achalasia: surgery or pneumatic dilation. *Gut* 2011;60:869–76.

6. Spechler SJ, Castell DO. Classification of oesophageal motility abnormalities. *Gut* 2001;49:145–51.
7. Richter JE. The diagnosis and misdiagnosis of Achalasia: it does not have to be so difficult. *Clin Gastroenterol Hepatol* 2011;9:1010–1.
8. Kessing BF, Bredenoord AJ, Smout AJ. Erroneous diagnosis of gastro-oesophageal reflux disease in achalasia. *Clin Gastroenterol Hepatol* 2011;9:1020–4.
9. Katz PO, Gerson LB, Vela MF. Guidelines for the diagnosis and management of gastroesophageal reflux disease. *Am J Gastroenterol* 2013;108:308–28; quiz 29.
10. Tucker HJ, Snape WJ Jr, Cohen S. Achalasia secondary to carcinoma: manometric and clinical features. *Ann Intern Med* 1978;89:315–8.
11. Rozman RW Jr, Achkar E. Features distinguishing secondary achalasia from primary achalasia. *Am J Gastroenterol* 1990;85:1327–30.
12. de Oliveira RB, Rezende Filho J, Dantas RO *et al.* The spectrum of esophageal motor disorders in Chagas' disease. *Am J Gastroenterol* 1995;90:1119–24.
13. Howard PJ, Maher L, Pryde A *et al.* Five year prospective study of the incidence, clinical features, and diagnosis of achalasia in Edinburgh. *Gut* 1992;33:1011–5.
14. Pandolfino JE, Kahrilas PJ. AGA technical review on the clinical use of esophageal manometry. *Gastroenterology* 2005;128:209–24.
15. Katz PO, Richter JE, Cowan R *et al.* Apparent complete lower esophageal sphincter relaxation in achalasia. *Gastroenterology* 1986;90:978–83.
16. Hirano I, Tatum RP, Shi G *et al.* Manometric heterogeneity in patients with idiopathic achalasia. *Gastroenterology* 2001;120:789–98.
17. Morera C, Nurko S. Heterogeneity of lower esophageal sphincter function in children with achalasia. *J Pediatr Gastroenterol Nutr* 2012;54:34–40.
18. Galey KM, Wilshire CL, Niebisch S *et al.* Atypical variants of classic achalasia are common and currently under-recognized: a study of prevalence and clinical features. *J Am Coll Surg* 2011;213:155–61; discussion 62–3.
19. Pandolfino JE, Kwiatek MA, Nealis T *et al.* Achalasia: a new clinically relevant classification by high-resolution manometry. *Gastroenterology* 2008;135:1526–33.
20. Scherer JR, Kwiatek MA, Soper NJ *et al.* Functional esophagogastric junction obstruction with intact peristalsis: a heterogeneous syndrome sometimes akin to achalasia. *J Gastrointest Surg* 2009;13:2219–25.
21. Dent J. A new technique for continuous sphincter pressure measurement. *Gastroenterology* 1976;71:263–7.
22. Staiano A, Clouse RE. Detection of incomplete lower esophageal sphincter relaxation with conventional point-pressure sensors. *Am J Gastroenterol* 2001;96:3258–67.
23. Ghosh SK, Pandolfino JE, Rice J *et al.* Impaired deglutitive EGJ relaxation in clinical esophageal manometry: a quantitative analysis of 400 patients and 75 controls. *Am J Physiol Gastrointest Liver Physiol* 2007;293:G878–85.
24. Clouse RE, Staiano A. Topography of the esophageal peristaltic pressure wave. *Am J Physiol* 1991;261 (4 Part 1): G677–84.
25. Clouse RE, Staiano A. Topography of normal and high-amplitude esophageal peristalsis. *Am J Physiol* 1993;265 (6 Part 1): G1098–107.
26. Salvador R, Costantini M, Zaninotto G *et al.* The preoperative manometric pattern predicts the outcome of surgical treatment for esophageal achalasia. *J Gastrointest Surg* 2010;14:1635–45.
27. Pratap N, Reddy DN. Can achalasia subtyping by high-resolution manometry predict the therapeutic outcome of pneumatic balloon dilatation?: author's reply. *J Neurogastroenterol Motil* 2011;17:205.
28. de Oliveira JM, Birgisson S, Doinoff C *et al.* Timed barium swallow: a simple technique for evaluating esophageal emptying in patients with achalasia. *AJR Am J Roentgenol* 1997;169:473–9.
29. Vaezi MF, Baker ME, Richter JE. Assessment of esophageal emptying post-pneumatic dilation: use of the timed barium esophagram. *Am J Gastroenterol* 1999;94:1802–7.
30. Vaezi MF, Baker ME, Achkar E *et al.* Timed barium oesophagram: better predictor of long term success after pneumatic dilation in achalasia than symptom assessment. *Gut* 2002;50:765–70.
31. Andersson M, Lundell L, Kostic S *et al.* Evaluation of the response to treatment in patients with idiopathic achalasia by the timed barium esophagram: results from a randomized clinical trial. *Dis Esophagus* 2009;22:264–73.
32. Dodds WJ, Stewart ET, Kishk SM *et al.* Radiologic amyl nitrite test for distinguishing pseudoachalasia from idiopathic achalasia. *AJR Am J Roentgenol* 1986;146:21–3.
33. Kahrilas PJ, Kishk SM, Helm JF *et al.* Comparison of pseudoachalasia and achalasia. *Am J Med* 1987;82:439–46.
34. Sandler RS, Bozymski EM, Orlando RC. Failure of clinical criteria to distinguish between primary achalasia and achalasia secondary to tumor. *Dig Dis Sci* 1982;27:209–13.
35. Goldblum JR, Whyte RI, Orringer MB *et al.* Achalasia. A morphologic study of 42 resected specimens. *Am J Surg Pathol* 1994;18:327–37.
36. Rodrigo S, Abboud G, Oh D *et al.* High intraepithelial eosinophil counts in esophageal squamous epithelium are not specific for eosinophilic esophagitis in adults. *Am J Gastroenterol* 2008;103:435–42.
37. Savarino E, Gemignani L, Zentilin P *et al.* Achalasia with dense eosinophilic infiltrate responds to steroid therapy. *Clin Gastroenterol Hepatol* 2011;9:1104–6.
38. Ziegler K, Sanft C, Friedrich M *et al.* Endosonographic appearance of the esophagus in achalasia. *Endoscopy* 1990;22:1–4.
39. Mittal RK, Kassab G, Puckett JL *et al.* Hypertrophy of the muscularis propria of the lower esophageal sphincter and the body of the esophagus in patients with primary motility disorders of the esophagus. *Am J Gastroenterol* 2003;98:1705–12.
40. Vaezi MF, Richter JE. Current therapies for achalasia: comparison and efficacy. *J Clin Gastroenterol* 1998;27:21–35.
41. Bortolotti M, Mari C, Lopilato C *et al.* Effects of sildenafil on esophageal motility of patients with idiopathic achalasia. *Gastroenterology* 2000;118:253–7.
42. Bortolotti M, Coccia G, Brunelli F *et al.* Isosorbide dinitrate or nifedipine: which is preferable in the medical therapy of achalasia? *Ital J Gastroenterol* 1994;26:379–82.
43. Pasricha PJ, Ravich WJ, Hendrix TR *et al.* Intrasphincteric botulinum toxin for the treatment of achalasia. *N Engl J Med* 1995;332:774–8.
44. Hoogerwerf WA, Pasricha PJ. Pharmacologic therapy in treating achalasia. *Gastrointest Endosc Clin N Am* 2001;11:311–24, vii.
45. Annese V, Bassotti G, Coccia G *et al.* A multicentre randomised study of intrasphincteric botulinum toxin in patients with oesophageal achalasia. *GISMAD Achalasia Study Group*. *Gut* 2000;46:597–600.
46. Vaezi MF, Richter JE, Wilcox CM *et al.* Botulinum toxin versus pneumatic dilatation in the treatment of achalasia: a randomised trial. *Gut* 1999;44:231–9.
47. Pasricha PJ, Rai R, Ravich WJ *et al.* Botulinum toxin for achalasia: long-term outcome and predictors of response. *Gastroenterology* 1996;110:1410–5.
48. Zaninotto G, Annese V, Costantini M *et al.* Randomized controlled trial of botulinum toxin versus laparoscopic Heller myotomy for esophageal achalasia. *Ann Surg* 2004;239:364–70.
49. Neubrand M, Scheurlen C, Schepke M *et al.* Long-term results and prognostic factors in the treatment of achalasia with botulinum toxin. *Endoscopy* 2002;34:519–23.
50. Patti MG, Feo CV, Arcerito M *et al.* Effects of previous treatment on results of laparoscopic Heller myotomy for achalasia. *Dig Dis Sci* 1999;44:2270–6.
51. Horgan S, Hudda K, Eubanks T *et al.* Does botulinum toxin injection make esophagomyotomy a more difficult operation? *Surg Endosc* 1999;13:576–9.
52. Smith CD, Stival A, Howell DL *et al.* Endoscopic therapy for achalasia before Heller myotomy results in worse outcomes than Heller myotomy alone. *Ann Surg* 2006;243:579–84; discussion 84–6.
53. Lambroza A, Schuman RW. Pneumatic dilation for achalasia without fluoroscopic guidance: safety and efficacy. *Am J Gastroenterol* 1995;90:1226–9.
54. Thomas V, Harish K, Sunilkumar K. Pneumatic dilation of achalasia cardia under direct endoscopy: the debate continues. *Gastrointest Endosc* 2006;63:734.
55. Lynch KL, Pandolfino JE, Howden CW *et al.* Major complications of pneumatic dilation and Heller myotomy for achalasia: single-center experience and systematic review of the literature. *Am J Gastroenterol* 2012;107:1817–25.
56. Ott DJ, Richter JE, Wu WC *et al.* Radiographic evaluation of esophagus immediately after pneumatic dilatation for achalasia. *Dig Dis Sci* 1987;32:962–7.
57. Vela MF, Richter JE, Khandwala F *et al.* The long-term efficacy of pneumatic dilatation and Heller myotomy for the treatment of achalasia. *Clin Gastroenterol Hepatol* 2006;4:580–7.
58. Campos GM, Vittinghoff E, Rabl C *et al.* Endoscopic and surgical treatments for achalasia: a systematic review and meta-analysis. *Ann Surg* 2009;249:45–57.
59. Gideon RM, Castell DO, Yarze J. Prospective randomized comparison of pneumatic dilatation technique in patients with idiopathic achalasia. *Dig Dis Sci* 1999;44:1853–7.
60. Hulselms M, Vanuytsel T, Degreef T *et al.* Long-term outcome of pneumatic dilation in the treatment of achalasia. *Clin Gastroenterol Hepatol* 2010;8:30–5.

61. Farhoomand K, Connor JT, Richter JE *et al*. Predictors of outcome of pneumatic dilation in achalasia. *Clin Gastroenterol Hepatol* 2004;2:389–94.
62. Eckardt VF, Aignherr C, Bernhard G. Predictors of outcome in patients with achalasia treated by pneumatic dilation. *Gastroenterology* 1992;103:1732–8.
63. Prata N, Kalapala R, Darisetty S *et al*. Achalasia cardia subtyping by high-resolution manometry predicts the therapeutic outcome of pneumatic balloon dilatation. *J Neurogastroenterol Motil* 2011;17:48–53.
64. Eckardt VF, Kanzler G, Westermeier T. Complications and their impact after pneumatic dilation for achalasia: prospective long-term follow-up study. *Gastrointest Endosc* 1997;45:349–53.
65. Guardino JM, Vela MF, Connor JT *et al*. Pneumatic dilation for the treatment of achalasia in untreated patients and patients with failed Heller myotomy. *J Clin Gastroenterol* 2004;38:855–60.
66. Ali A, Pellegrini CA. Laparoscopic myotomy: technique and efficacy in treating achalasia. *Gastrointest Endosc Clin N Am* 2001;11:347–58, vii.
67. Morino M, Rebecchi F, Festa V *et al*. Preoperative pneumatic dilatation represents a risk factor for laparoscopic Heller myotomy. *Surg Endosc* 1997;11:359–61.
68. Richards WO, Torquati A, Holzman MD *et al*. Heller myotomy versus Heller myotomy with Dor fundoplication for achalasia: a prospective randomized double-blind clinical trial. *Ann Surg* 2004;240:405–12; discussion 12–5.
69. Torquati A, Richards WO, Holzman MD *et al*. Laparoscopic myotomy for achalasia: predictors of successful outcome after 200 cases. *Ann Surg* 2006;243:587–91; discussion 91–3.
70. Stefanidis D, Richardson W, Farrell TM *et al*. SAGES guidelines for the surgical treatment of esophageal achalasia. *Surg Endosc* 2012;26:296–311.
71. Rawlings A, Soper NJ, Oelschlager B *et al*. Laparoscopic Dor versus Toupet fundoplication following Heller myotomy for achalasia: results of a multicenter, prospective, randomized-controlled trial. *Surg Endosc* 2012;26:18–26.
72. Sweet MP, Nipomnick I, Gasper WJ *et al*. The outcome of laparoscopic Heller myotomy for achalasia is not influenced by the degree of esophageal dilatation. *J Gastrointest Surg* 2008;12:159–65.
73. Mineo TC, Ambrogi V. Long-term results and quality of life after surgery for oesophageal achalasia: one surgeon's experience. *Eur J Cardiothorac Surg* 2004;25:1089–96.
74. Glatz SM, Richardson JD. Esophagectomy for end stage achalasia. *J Gastrointest Surg* 2007;11:1134–7.
75. Molena D, Yang SC. Surgical management of end-stage achalasia. *Semin Thorac Cardiovasc Surg* 2012;24:19–26.
76. Kadakia SC, Wong RK. Pneumatic balloon dilation for esophageal achalasia. *Gastrointest Endosc Clin N Am* 2001;11:325–46, vii.
77. Duranceau A, Liberman M, Martin J *et al*. End-stage achalasia. *Dis Esophagus* 2012;25:319–30.
78. Leyden JE, Moss AC, MacMathuna P. Endoscopic pneumatic dilation versus botulinum toxin injection in the management of primary achalasia. *Cochrane Database Syst Rev* 2006;(4): CD005046.
79. Boeckxstaens GE, Annesse V, des Varannes SB *et al*. Pneumatic dilation versus laparoscopic Heller's myotomy for idiopathic achalasia. *N Engl J Med* 2011;364:1807–16.
80. Imperiale TF, O'Connor JB, Vaezi MF *et al*. A cost-minimization analysis of alternative treatment strategies for achalasia. *Am J Gastroenterol* 2000;95:2737–45.
81. O'Connor JB, Singer ME, Imperiale TF *et al*. The cost-effectiveness of treatment strategies for achalasia. *Dig Dis Sci* 2002;47:1516–25.
82. Karanicolas PJ, Smith SE, Incullet RI *et al*. The cost of laparoscopic myotomy versus pneumatic dilatation for esophageal achalasia. *Surg Endosc* 2007;21:1198–206.
83. Kostic S, Johnsson E, Kjellin A *et al*. Health economic evaluation of therapeutic strategies in patients with idiopathic achalasia: results of a randomized trial comparing pneumatic dilatation with laparoscopic cardiomyotomy. *Surg Endosc* 2007;21:1184–9.
84. Richter JE. Update on the management of achalasia: balloons, surgery and drugs. *Expert Rev Gastroenterol Hepatol* 2008;2:435–45.
85. Inoue H, Minami H, Kobayashi Y *et al*. Peroral endoscopic myotomy (POEM) for esophageal achalasia. *Endoscopy* 2010;42:265–71.
86. Inoue H, Kudo SE. Per-oral endoscopic myotomy (POEM) for 43 consecutive cases of esophageal achalasia. *Nihon Rinsho* 2010;68:1749–52.
87. von Renteln D, Inoue H, Minami H *et al*. Peroral endoscopic myotomy for the treatment of achalasia: a prospective single center study. *Am J Gastroenterol* 2012;107:411–7.
88. Swanstrom LL, Rieder E, Dunst CM. A stepwise approach and early clinical experience in peroral endoscopic myotomy for the treatment of achalasia and esophageal motility disorders. *J Am Coll Surg* 2011;213:751–6.
89. Li YD, Cheng YS, Li MH *et al*. Temporary self-expanding metallic stents and pneumatic dilation for the treatment of achalasia: a prospective study with a long-term follow-up. *Dis Esophagus* 2010;23:361–7.
90. Fekete F, Breil P, Tossen JC. Reoperation after Heller's operation for achalasia and other motility disorders of the esophagus: a study of eighty-one reoperations. *Int Surg* 1982;67:103–10.
91. Miller DL, Allen MS, Trastek VF *et al*. Esophageal resection for recurrent achalasia. *Ann Thorac Surg* 1995;60:922–5; discussion 5–6.
92. Ellis FH Jr, Olsen AM. Achalasia of the esophagus. *Major Probl Clin Surg* 1969;9:1–221.
93. Peters JH, Kauer WK, Crookes PF *et al*. Esophageal resection with colon interposition for end-stage achalasia. *Arch Surg* 1995;130:632–636; discussion 6–7.
94. Orringer MB, Stirling MC. Esophageal resection for achalasia: indications and results. *Ann Thorac Surg* 1989;47:340–5.
95. Eckardt VF, Hoischen T, Bernhard G. Life expectancy, complications, and causes of death in patients with achalasia: results of a 33-year follow-up investigation. *Eur J Gastroenterol Hepatol* 2008;20:956–60.
96. Vela MF, Richter JE, Wachsberger D *et al*. Complexities of managing achalasia at a tertiary referral center: use of pneumatic dilatation, Heller myotomy, and botulinum toxin injection. *Am J Gastroenterol* 2004;99:1029–36.
97. Bonatti H, Hinder RA, Klocker J *et al*. Long-term results of laparoscopic Heller myotomy with partial fundoplication for the treatment of achalasia. *Am J Surg* 2005;190:874–8.
98. Costantini M, Zaninotto G, Guirroli E *et al*. The laparoscopic Heller-Dor operation remains an effective treatment for esophageal achalasia at a minimum 6-year follow-up. *Surg Endosc* 2005;19:345–51.
99. Zerbib F, Thetiot V, Richey F *et al*. Repeated pneumatic dilations as long-term maintenance therapy for esophageal achalasia. *Am J Gastroenterol* 2006;101:692–7.
100. Leeuwenburgh I, Scholten P, Alderliesten J *et al*. Long-term esophageal cancer risk in patients with primary achalasia: a prospective study. *Am J Gastroenterol* 2010;105:2144–9.
101. Sandler RS, Nyren O, Ekblom A *et al*. The risk of esophageal cancer in patients with achalasia. A population-based study. *JAMA* 1995;274:1359–62.
102. Hirota WK, Zuckerman MJ, Adler DG *et al*. ASGE guideline: the role of endoscopy in the surveillance of premalignant conditions of the upper GI tract. *Gastrointest Endosc* 2006;63:570–80.
103. Eckardt AJ, Eckardt VF. Editorial: Cancer surveillance in achalasia: better late than never? *Am J Gastroenterol* 2010;105:2150–2.