



**Table 1. Recommendation statements***Diagnosis of small bowel bleeding*

1. Second-look upper endoscopy should be considered in cases of recurrent hematemesis, melena, or a previously incomplete exam (strong recommendation, low level of evidence).
2. Second-look colonoscopy should be considered in the setting of recurrent hematochezia or if a lower source is suspected (conditional recommendation, very low level of evidence).
3. If the second-look examinations are normal, the next step should be a small bowel evaluation (strong recommendation, moderate level of evidence).
4. Push enteroscopy can be performed as a second-look examination in the evaluation of suspected small bowel bleeding (conditional recommendation, moderate level of evidence).
5. Video capsule endoscopy (VCE) should be considered as a first-line procedure for SB evaluation after upper and lower GI sources have been excluded, including second-look endoscopy when indicated (strong recommendation, moderate level of evidence).
6. Owing to the lower detection rate of lesions in the duodenum and proximal jejunum with VCE, push enteroscopy should be performed if proximal lesions are suspected (strong recommendation, very low level of evidence).
7. Total deep enteroscopy should be attempted if there is a strong suspicion of a small bowel lesion based on clinical presentation (strong recommendation, moderate level of evidence).
8. Any method of deep enteroscopy can be used when endoscopic evaluation and therapy is required based on similar diagnostic yields (strong recommendation, high level of evidence).
9. Intraoperative enteroscopy is a highly sensitive but invasive diagnostic and effective therapeutic procedure. Its usage should be limited to scenarios where enteroscopy cannot be performed, such as patients with prior surgeries and intestinal adhesions (strong recommendation, low level of evidence).
10. VCE should be performed before deep enteroscopy to increase diagnostic yield. Initial deep enteroscopy can be considered in cases of massive hemorrhage or when VCE is contraindicated (strong recommendation, high level of evidence).

*Usage of radiographic examinations*

11. Barium studies should not be performed in the evaluation of small bowel bleeding (strong recommendation, high level of evidence).
12. Computed tomographic enterography (CTE) should be performed in patients with suspected small bowel bleeding and negative capsule endoscopy because of higher sensitivity for the detection of mural-based small bowel masses, superior capability to locate small bowel masses, and ability to guide subsequent deep enteroscopy (strong recommendation, low level of evidence).
13. CT is preferred over magnetic resonance (MR) imaging for the evaluation of suspected small bowel bleeding. MR can be considered in patients with contraindications for CT or to avoid radiation exposure in younger patients (conditional recommendation, very low level of evidence).
14. CTE could be considered before VCE in the setting of established inflammatory bowel disease, prior radiation therapy, previously small bowel surgery, and/or suspected small bowel stenosis (strong recommendation, very low level of evidence).
15. In patients with suspected small bowel bleeding and negative VCE examination, CTE should be performed if there is high clinical suspicion for a small bowel source despite performance of a prior standard CT of the abdomen (conditional recommendation, very low level of evidence).
16. In acute overt massive GI bleeding, conventional angiography should be performed emergently for hemodynamically unstable patients (strong recommendation, low level of evidence).
17. In hemodynamically stable patients with evidence of active bleeding, multiphasic CT (CTA) can be performed to identify the site of bleeding and guide further management (strong recommendation, low level of evidence).
18. In patients with acute overt GI bleeding and slower rates of bleeding (0.1–0.2 ml/min), or uncertainty if actively bleeding, tagged red blood cell scintigraphy should be performed if deep enteroscopy or VCE are not performed to guide timing of angiography (strong recommendation, moderate level of evidence).
19. In brisk active overt bleeding, CT angiography (CTA) is preferred over CTE (conditional recommendation, very low level of evidence).
20. Conventional angiography should not be performed as a diagnostic test in patients without overt bleeding (conditional recommendation, very low level of evidence).
21. Provocative angiography can be considered in the setting of ongoing overt bleeding and negative VCE, deep enteroscopy, and/or CT examination (conditional recommendation, very low level of evidence).
22. In younger patients with ongoing overt bleeding and normal testing with capsule endoscopy and enterography examinations, a Meckel's scan should be performed (conditional recommendation, very low level of evidence).

*Treatment and outcomes*

23. If a source of bleeding is found by VCE and/or deep enteroscopy in the small intestine that is associated with significant ongoing anemia or active bleeding, then the patient should be managed with endoscopic therapy (strong recommendation, low level of evidence).
24. If after appropriate small bowel investigation no source of bleeding is found, the patient should be managed conservatively with oral iron or by intravenous infusion as is dictated by the severity and persistence of the associated iron-deficiency anemia. In this context, a small vascular lesion found on capsule endoscopy does not always need treatment (strong recommendation, very low level of evidence).

Table 1 continued on following page

**Table 1. Recommendation statements**

25. If bleeding persists in either of the above situations with worsening anemia, a further diagnostic workup should include a repeated upper and lower endoscopy, video capsule examination, deep enteroscopy, CT or MRI enterography as is appropriate for the clinical situation and availability of investigative devices (strong recommendation, low level of evidence).
26. If bleeding persists or recurs or a lesion cannot be localized consideration may be given to medical treatment with iron, somostatin analogs, or antiangiogenic therapy (strong recommendation, moderate level of evidence).
27. Anticoagulation and/or antiplatelet therapy should be discontinued if possible in patients with small bowel hemorrhage (conditional recommendation, very low level of evidence).
28. Surgical intervention in massive small bowel bleeding may be useful, but is greatly aided with presurgical localization of the site of bleeding by marking the lesion with a tattoo (strong recommendation, low level of evidence).
29. Intraoperative enteroscopy should be available at the time of the surgical procedure to provide assistance to localize the source of bleeding and to perform endoscopic therapy (conditional recommendation, low level of evidence).
30. Patients with Heyde's syndrome (aortic stenosis and angiodystasia) and ongoing bleeding should undergo aortic valve replacement (conditional recommendation, moderate level of evidence).
31. For patients with recurrence of small bowel bleeding, endoscopic management can be considered depending on the patient's clinical course and response to prior therapy (conditional recommendation, moderate level of evidence).

CTA, CT angiography; CTE, computed tomographic enterography; MRI, magnetic resonance imaging; VCE, video capsule endoscopy.

and "telangiectasia." The full literature search strategy is demonstrated in the **Appendix**.

To evaluate the level of evidence and strength of recommendations, we used the Grading of Recommendations Assessment, Development, and Evaluation (GRADE) system (3). The level of evidence could range from "high" (implying that further research was unlikely to change the authors' confidence in the estimate of the effect) to "moderate" (further research would be likely to have an impact on the confidence in the estimate of effect), "low" (further research would be expected to have an important impact on the confidence in the estimate of the effect and would be likely to change the estimate), or "very low" (any estimate of effect is very uncertain). The strength of a recommendation was graded as "strong" when the desirable effects of an intervention clearly outweigh the undesirable effects and as "conditional" when there is uncertainty about the trade-offs. We preferentially used meta-analyses or systematic reviews when available, followed by clinical trials and retrospective cohort studies. To determine the level of evidence, we entered data from the papers of highest evidence into the GRADE program (accessible at <http://www.gradepro.org>). The recommendation statements from this guideline are shown in **Table 1**. Summary statements, when listed, are designed to be descriptive in nature without associated evidence-based ratings.

### Definition of overt or occult small bowel bleeding

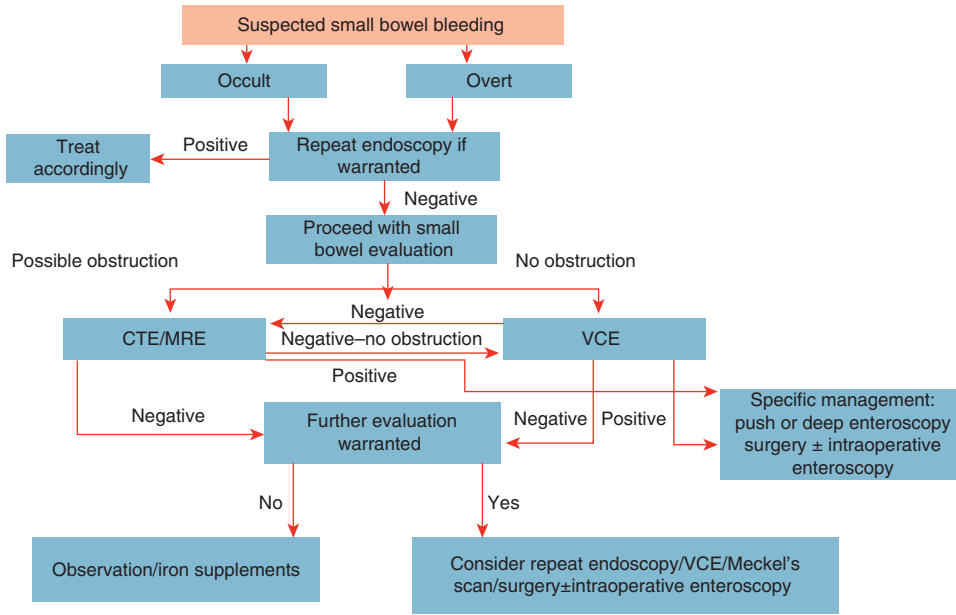
#### Summary statements

1. A source of small bowel bleeding should be considered in patients with overt or occult GI hemorrhage after performance of a normal upper and lower endoscopic examination.
2. Patients should be classified as having small bowel bleeding if a source of bleeding is identified distal to the ampulla of Vater and/or proximal to the ileocecal valve.
3. After normal upper and lower endoscopic examinations and before performance of capsule endoscopy, patients should be classified as having "potential small bowel bleeding."

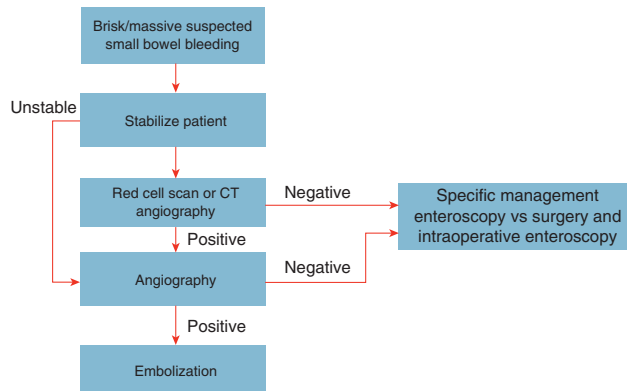
4. "Overt small bowel bleeding" refers to patients presenting with either melena or hematochezia with a source of bleeding identified in the small intestine. The term "occult small bowel bleeding" can be reserved for patients presenting with iron-deficiency anemia with or without guaiac-positive stools who are found to have a small bowel source of bleeding.
5. The term "obscure GI bleeding" should be reserved for patients not found to have a source of bleeding after performance of standard upper and lower endoscopic examinations, small bowel evaluation with VCE and/or enteroscopy, and radiographic testing.

The traditional definition of "OGIB" before the introduction of VCE and deep enteroscopy included patients with overt or occult GI bleeding who underwent normal upper and lower endoscopic examinations in addition to a small bowel series that did not reveal a source of bleeding. Patients with overt obscure bleeding were defined as patients presenting with either hematochezia or melena, whereas patients with occult obscure bleeding were classified based on the presence of a positive fecal occult blood test with or without iron-deficiency anemia.

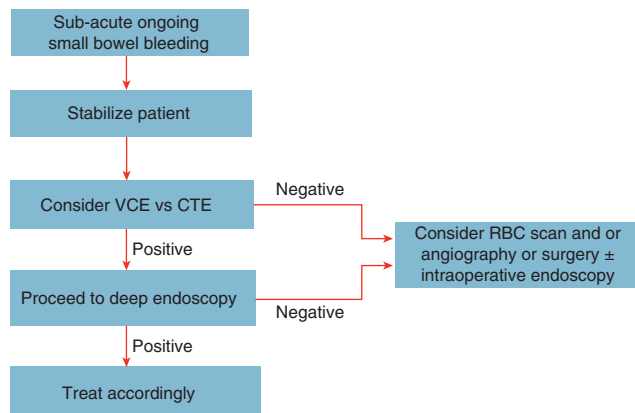
With the introduction of VCE in the United States in 2001 and deep enteroscopy in 2004, the majority (~75%) of patients previously classified as having obscure bleeding were found to have sources of bleeding identified in the small intestine (4). The diagnostic yield included any causes of bleeding detected distal to the ampulla of Vater or proximal to the ileocecal valve by any testing modality including push enteroscopy, ileoscopy, deep enteroscopy, VCE, angiography, or an enterography examination. We would therefore propose that patients with small bowel sources identified be classified as having small bowel bleeding, reserving the prior term of OGIB for patients without a source of bleeding identified after comprehensive evaluation of the small bowel as described in the sections below.



**Figure 1.** Algorithm for suspected small bowel bleeding. CTE, computed tomographic enterography; MRE, magnetic resonance enterography; VCE, video capsule endoscopy.



**Figure 2.** Algorithm for brisk or massive suspected small bowel bleeding. CT, computed tomography.



**Figure 3.** Algorithm for sub-acute ongoing suspected small bowel bleeding. CTE, computed tomographic enterography; RBC, red blood cell; VCE, video capsule endoscopy.

**Table 2. Causes of small bowel bleeding**

Common causes		Rare causes
Under age 40 years	Over age 40 years	Henoch–Schoenlein purpura
Inflammatory bowel disease	Angioectasia	Small bowel varices and/or portal hypertensive enteropathy
Dieulafoy's lesions	Dieulafoy's lesions	Amyloidosis
Neoplasia	Neoplasia	Blue rubber bleb nevus syndrome
Meckel's diverticulum	NSAID ulcers	Pseudoxanthoma elasticum
Polyposis syndromes		Osler–Weber–Rendu syndrome
		Kaposi's sarcoma with AIDS
		Plummer–Vinson syndrome
		Ehlers–Danlos syndrome
		Inherited polyposis syndromes (FAP, Peutz–Jeghers)
		Malignant atrophic papulosis
		Hematochezia
		Aorto-enteric fistula
		Hemosuccus entericus

FAP, familial adenomatous polyposis; NSAID, nonsteroidal anti-inflammatory drug.

## Epidemiology and natural history of small bowel bleeding

### Summary statements

1. The type of lesion responsible for small bowel bleeding is dependent on patient age but not gender or ethnicity.
2. Small bowel angioectasia are the most common cause of small bowel bleeding.
3. Risk factors for angioectasia include advancing age, presence of aortic stenosis, chronic renal failure, left ventricular assist devices, and other hereditary disorders.
4. Risk factors for recurrent small bowel bleeding from angioectasia include number of lesions, advanced age, presence of comorbid conditions, and anticoagulant therapy.

**Prevalence and etiology of small bowel bleeding.** The prevalence of small bowel lesions has been estimated to be ~5–10% in patients presenting with GI bleeding (1,2). Details pertaining to the clinical presentation are critically important in the determination of the etiology. A history of a bleeding diathesis as with von Willebrand disease and medication usage including aspirin, nonsteroidal anti-inflammatory drugs, anticoagulants, and/or other antiplatelet agents also can lend clues to the diagnosis. Knowledge of comorbidities such as valvular heart disease and prior procedures/surgeries such as liver biopsy, liver transplantation, abdominal aortic aneurysm repair, or bowel resection again can be very helpful. Common causes of small bowel bleeding are listed in **Table 2** and are found in ~75% of patients with suspected small bowel bleeding (5). Based on a 2008 meta-analysis combining data from Western and Asian countries and reporting yields on both VCE

and double-balloon enteroscopy (DBE) (4), the prevalence of small bowel vascular lesions based on 10 studies was 24% for both VCE ( $N=371$ ) and DBE ( $N=364$ ). For inflammatory findings, the yield was 18% for VCE ( $N=343$ ) and 16% for DBE ( $N=336$ ), and the yield was 11% for mass lesions (VCE,  $N=343$  and DBE,  $N=336$ ). An analysis comparing diagnostic yields from Western compared to Asian countries demonstrated that patients undergoing DBE in Asian countries were more likely to have neoplastic findings, whereas angioectasia were more common in Western countries.

Age has been known to be a determinant for the type of small bowel pathology detected. Patients under the age of 40 years are more likely to have inflammatory bowel disease or Meckel's diverticulum. Small bowel neoplasms (e.g., GI stromal cell tumor, lymphoma, carcinoid, adenocarcinoma, or other polypoid lesions) and Dieulafoy's lesions can occur in both younger and older patient cohorts (6–11). Angioectasia, other vascular lesions, and ulcers secondary to anti-inflammatory agents are more likely in patients over the age of 40 years. Data regarding ethnicity and small bowel findings has not been extensively published to date.

**Differences in findings between patients with overt or occult small bowel bleeding.** Studies using VCE and deep enteroscopy have demonstrated higher diagnostic yields for patients with overt bleeding compared with patients with occult bleeding. For patients with prior overt bleeding, the diagnostic yield was less than that for current overt bleeders, and decreased substantially with time. In a 2004 study by Pennazio *et al.* (12) of 100 patients undergoing VCE, the diagnostic yield was 92% for patients with overt bleeding, 44% for occult bleeders, 67% for patients with prior overt bleeding who were studied within 10–14 days, and 33% at 3–4 weeks postbleeding episode. In a 2010 study of 200 patients with bleeding undergoing DBE, the diagnostic yield was 77% for overt bleeding, 67% for patients with occult hemorrhage, and 59% for patients with prior overt bleeding (13).

In addition to higher diagnostic yields for patients with overt bleeding, recurrence rates may be higher in patients presenting with overt bleeding. In a multicenter US study assessing long-term outcomes post-DBE, recurrence of overt bleeding occurred in 34% of patients presenting with overt hemorrhage compared with 13% of patients with occult bleeding at 12 months postprocedure ( $P=0.06$ ) (14). These recurrence rates, however, were not significant at 30 months of follow-up (27% vs. 20%,  $P=NS$ ).

**Rare causes and non-small bowel sources of bleeding.** Rare causes of small bowel bleeding are shown in **Table 2**. Patients with disorders associated with portal hypertension and/or with endoscopic evidence of varices or portal hypertension have also demonstrated portal hypertensive changes in the small bowel on VCE or enteroscopy studies (15). Other rare causes of bleeding from the small bowel have included Kaposi's sarcoma associated with acquired immunodeficiency syndrome, Plummer–Vinson syndrome, pseudoxanthoma elasticum, Ehlers–Danlos syndrome, Henoch–Schoenlein purpura, neurofibromatosis, malignant atrophic papulosis, and other inherited polyposis syndromes. A family history of polyposis syndromes may provide important

clues to the underlying etiology of small bowel bleeding. Physical examination, including a detailed dermatological evaluation, may also be useful in the diagnosis of systemic syndromes, including hereditary hemorrhagic telangiectasia and blue-rubber bleb nevus syndrome. Uncommon non-small bowel sources of obscure GI bleeding not shown in the table have included hematemesis, hemosuccus pancreaticus, and aortoenteric fistulae.

Prior clinical guidelines have listed celiac disease as a cause of small bowel bleeding (16), but there is emerging evidence that celiac disease leads to iron-deficiency anemia because of malabsorption and not because of the presence of occult GI bleeding (17). Although complications associated with celiac disease such as ulcerative jejunitis, lymphoma, and/or adenocarcinoma can cause bleeding from the small intestine, the entity of celiac disease is no longer listed as a cause of small bowel bleeding.

### Diagnosis of small bowel bleeding (Figure 1)

#### Recommendations

1. Second-look upper endoscopy should be considered in cases of recurrent hematemesis, melena, or a previously incomplete exam (strong recommendation, low level of evidence).
2. Second-look colonoscopy should be considered in the setting of recurrent hematochezia or if a lower source is suspected (conditional recommendation, very low level of evidence).
3. If the second-look examinations are normal, the next step should be a small bowel evaluation (strong recommendation, moderate level of evidence).
4. Push enteroscopy can be performed as a second-look examination in the evaluation of suspected small bowel bleeding (conditional recommendation, moderate level of evidence).
5. VCE should be considered a first-line procedure for small bowel (SB) evaluation after upper and lower GI sources have been excluded, including second-look endoscopy when indicated (strong recommendation, moderate level of evidence).
6. Owing to the lower detection rate of lesions in the duodenum and proximal jejunum with VCE, push enteroscopy should be performed if proximal lesions are suspected (strong recommendation, very low level of evidence).
7. Total deep enteroscopy should be attempted if there is a strong suspicion of a small bowel lesion based on clinical presentation or abnormal VCE study (strong recommendation, moderate level of evidence).
8. Any method of deep enteroscopy can be used when endoscopic evaluation and therapy is required based on similar diagnostic yields (strong recommendation, high level of evidence).
9. Intraoperative enteroscopy (IOE) is a highly sensitive but invasive diagnostic and effective therapeutic procedure. Its usage should be limited to scenarios where enteroscopy cannot be performed, such as patients with prior surgeries and intestinal adhesions (strong recommendation, low level of evidence).
10. VCE should be performed before deep enteroscopy to increase diagnostic yield. Initial deep enteroscopy can be considered in cases of massive hemorrhage or when VCE is contraindicated (strong recommendation, high level of evidence).

The main limitations of SB evaluation in the past were related to its length (>6 m) and limited intubation with conventional endoscopy; these shortcomings have been largely overcome by recent advances in endoscopic technology, including VCE, deep enteroscopy (including DBE, SB enteroscopy, and spiral enteroscopy), and radiologic modalities including CT enterography (CTE) and MR enterography. These new advances, as well as the capacity to successfully perform endoscopic therapeutic interventions, have led to significant improvement in the management of patients with small bowel bleeding, and a decline in invasive surgical procedures (IOE, laparoscopy, and exploratory laparotomy) (18–21).

#### Second-look endoscopy

Most small intestinal bleeding is undramatic in presentation and either presents as stable overt or occult bleeding. The prior literature demonstrated that a high percentage of patients designated as having “potential small bowel bleeding” were found to have missed bleeding sources within reach of conventional upper and lower endoscopy including diagnostic yields ranging from 2 to 25% in patients undergoing repeat esophagogastroduodenoscopy and 6 to 23% on repeat colonoscopy (22–24). More recent studies using DBE and capsule endoscopy have also confirmed these findings (25–30).

Most overt bleeding can be evaluated first with a second-look procedure to exclude upper and lower bleeding that can be readily reached with a standard endoscope. Instead of repeating an upper endoscopy, a push enteroscopy may be performed to examine the distal duodenum and proximal jejunum. During the colonoscopy, every effort should be made to intubate the terminal ileum to visualize the ileal mucosa and to inspect for blood coming from a more proximal location of the small intestine. For expediency of work up, it is sometimes appropriate to use VCE as the first-line test after having had a negative upper endoscopy and colonoscopy. In fact, one study did not show that second-look endoscopy was cost effective (31). However, the distal duodenum and proximal jejunum would still need to be examined unless the VCE reveals the source of the suspected small bowel bleeding.

#### Push enteroscopy

Push enteroscopy is an extended upper endoscopy performed with a long endoscope such as a pediatric colonoscope (32) or with a commercially available push enteroscope, which is typically 250 cm in length. Push enteroscopy allows only limited evaluation of the proximal SB, ~70 cm distal to the ligament of Treitz. Push enteroscopy using a colonoscope typically can be passed 45–60 cm beyond the ligament of Treitz (33). When push enteroscopy is carried out with the variable stiffness design, it reaches a deeper distance of nearly 90 cm (34). The diagnostic yield of push enteroscopy is reported to range from 3 to 70%, with the majority of SB findings being vascular lesions (16,35–38). Interestingly, most of the lesions diagnosed on push enteroscopy have been found in locations accessible to standard esophagogastroduodenoscopy, emphasizing the importance of second-look endoscopy (22,39). When a dedicated push enteroscope is used, it may be performed with an overtube designed to reduce looping in the

stomach and stiffen the enteroscope for deeper passage (40). Although the use of an overtube may allow for deeper SB intubation up to 150 cm, it does not appear to increase the diagnostic yield of the test (41). The main disadvantages of this exam include looping of the enteroscope and patient discomfort. Its role is currently limited to endoscopic therapeutics in those patients who have only proximal SB lesions detected on VCE. Although it has only a limited range, push enteroscopy is an ideal second-look procedure because of the ability to examine the distal duodenum and proximal jejunum, a SB segment that is not always well seen with VCE.

### Endoscopic visualization of the small intestine

**Video capsule endoscopy.** Introduced for clinical use in the United States in 2001, VCE is now available throughout the world. There are now four VCE platforms, with three available for clinical use in the United States. The VCE measures 26×11 mm<sup>2</sup>, and has the capacity to take images at the rate of 2 frames/s, over an 8–12 h period. Images are transmitted to a recording device, and can be downloaded and viewed on a computer station with the appropriate software. Capsule endoscopy allows noninvasive evaluation of the entire SB in 79–90% of patients, with a diagnostic yield of 38–83% in patients with suspected small bowel bleeding (42). The main utility of this test lies in its high positive (94–97%) and negative predictive value (83–100%) in the evaluation of GI bleeding (12,43). Findings on VCE leading to endoscopic or surgical intervention or a change in medical management have been reported in 37–87% of patients (12,44). In addition, 50–66% of patients have been reported to remain transfusion free without recurrent bleed at follow-up, after undergoing VCE-directed interventions (43,45). The rebleeding rate ranges from 6 to 27% in patients who have had a negative capsule study (46–48).

The yield of VCE may be influenced by multiple factors, with a higher likelihood of positive findings in patients with a hemoglobin <10 g/dl, longer duration of bleeding (>6 months), more than one episode of bleeding, overt as compared with occult bleeding (60% vs. 46%), and performance of VCE within 2 weeks of the bleeding episode (91% vs. 34%) (49–52). There is also evidence that VCE within 48 to 72 h of overt suspected small bowel bleeding has the greatest yield for lesion detection (53–55). A more recent study confirmed that overt bleeding was the strongest predictor of a positive capsule study, but male sex, age >60 years, and inpatient status were also independent predictors (56). Other risk factors for a positive capsule include cardiac and renal comorbidities. Although usually performed for intermittent overt bleeding, at least one study suggests that it may be useful in the emergency situation of severe overt suspected small bowel hemorrhage (57).

The main limitations of VCE include lack of therapeutic capabilities, inability to control its movement through the GI tract, and the difficulty in localizing the lesion. The other limitations of VCE include a lack of specificity with 14% incidental findings in healthy volunteers (58) and a 10–36% false-negative rate (59,60). Finally, VCE fails to identify the major papilla in a majority of cases (61,62) and therefore may miss important duodenal lesions because of rapid transit through the duodenal loop. This deficiency may be

improved to 60% if a dual camera capsule is used (63). Nonetheless, VCE does miss clinically important duodenal and proximal jejunal lesions (64–67), and thus cannot be solely relied upon for exclusion of bleeding lesions in these areas. However, there are studies to suggest that repeat VCE may be of benefit and increase the diagnostic yield, even when the first study is negative (68–70). A prospective study again showed that repeat VCE may be beneficial, particularly when the bleeding changes from occult to overt or there is a hemoglobin drop  $\geq 4$  g/dl (71).

VCE is very well tolerated by patients (72). Its main complication is capsule retention, which may occur in roughly 1.5% of patients undergoing evaluations for potential small bowel bleeding sources (73). VCE, however, may be complicated by retention in up to 13% in Crohn's disease patients, which limits its use in patients with suspected obstruction or strictures until patency is documented (74,75). Screening SB radiographs have not been able to eliminate this problem, although the patency capsule may be useful (76). The most serious complication reported with VCE is perforation, which fortunately has been exceedingly rare (77).

### Deep enteroscopy

**Balloon-assisted enteroscopy.** Balloon-assisted enteroscopy uses the principle of push and pull enteroscopy, and includes DBE and SBE as described further below (78). As the name suggests, both of the balloon enteroscopes have an overtube, with balloons at their distal ends. The DBE uses a balloon on the end of the scope and the overtube. The SBE works by using the tip of the scope as an anchor along with the single balloon. The balloons on the DBE and overtube are composed of latex, whereas the balloon on the SBE overtube is made of silicone. Therefore, for patients with latex allergy, SBE should be performed. The enteroscope in both systems has a working length of 200 cm with an outer diameter of 9.4 mm. The overtube is 140 cm in length.

The technique of balloon-assisted enteroscopy involves a series of steps called advancement cycles, described below. Balloon-assisted enteroscopy can be performed via the oral and rectal approach. It has been mainly studied in adults between the ages of 18 and 70 years but appears to be safe in the elderly population (over 70 years in age), as well as in children (79,80).

### Double-balloon enteroscopy

DBE was first described in 2001 by Yamamoto *et al.* (81). The equipment has been available for clinical use in the United States since 2004. DBE allows deeper intubation of the SB compared with traditional endoscopes. It can be advanced a distance of ~240–360 cm distal to the pylorus with the oral approach and 102–140 cm proximal to the ileocecal valve with the rectal approach. This compares to a distance of 90–150 cm with the push enteroscope and 50–80 cm with ileoscopy (51,82). It has the additional advantage over VCE of both diagnostic and therapeutic capabilities, including biopsies, tattoo, hemostasis, polypectomy, dilation, and foreign body removal (including retained capsules) (83–85). The 2.8 mm accessory channel allows passage of virtually all standard-caliber, through-the-scope, diagnostic and therapeutic instruments (86).

To perform DBE, the enteroscope and overtube are introduced into the small bowel typically past the ampulla, and the balloon on the overtube is inflated. The enteroscope is then further advanced into the small bowel. The balloon on the DBE enteroscope is then inflated. The overtube is subsequently advanced over the enteroscope. Now both overtube and enteroscope are drawn back (with both balloons inflated on DBE), which allows the small bowel to plicate over the enteroscope. By repeating this series of steps, a longer distance can be traversed as compared with conventional endoscopy.

The diagnostic yield of DBE ranges from 60 to 80% in patients with suspected small bowel bleeding and other SB disorders. Successful performance of endoscopic therapeutic interventions has been reported in 40–73% of patients (51,87,88). A more recent study confirms these earlier findings (89). DBE has generally been used for small bowel evaluation in the chronic stable or mildly to moderately active bleeding situation because of its small suction channel. However, a small recent study actually suggests that emergency DBE is technically feasible and may facilitate the diagnosis and management of patients with massive overt small bowel hemorrhage (90). A more recent study also suggests that urgent DBE is better than non-urgent DBE and is associated with a lower recurrent bleeding rate (91). In addition, one study suggests that repeat DBE from the same direction may also be beneficial, particularly if the patient had a prior positive DBE (92).

Total enteroscopy with DBE is defined as complete evaluation of the small bowel either with a single approach or combined oral and rectal approach. The decision to perform total enteroscopy is usually dependent on the discretion of the endoscopist, degree of clinical suspicion for a small bowel lesion, and inability to detect the lesion using a single approach. Despite the best attempts of the endoscopist, total enteroscopy may not be feasible in all patients, with a reported success rate ranging from 16 to 86% (81,93). A prospective, randomized study demonstrated that DBE had a significantly higher total enteroscopy rate than SBE (94).

The main limitations of DBE include its invasive nature, prolonged procedure time, and requirement for additional personnel. The reported complication rate for diagnostic procedures is 0.8%, and up to 4% if therapeutics such as electrocoagulation, polypectomy, or dilation are performed. The main complications reported with this technique are ileus, pancreatitis, and perforation, usually associated with large polypectomies (51,84,95). Pancreatitis is the most common complication of the peroral diagnostic DBE, occurring in at least 0.3% of patients (95). Perforation appears to be more common in patients with intestinal anastomosis and SB polypectomy (96,97). Postprocedure bloating and abdominal pain were once a common occurrence, but they have been rarely reported by patients as the use of carbon dioxide as the insufflating gas because of rapid diffusion of the gas across the intestinal mucosa (98,99). A recent large prospective database suggested an overall complication rate of 1.2% (100).

### Single-balloon enteroscopy

Two years after the launch of the commercially available double-balloon system, SBE was introduced. The theory and technique

of SBE are very similar to that of DBE; the key difference being that there is no balloon on the end of the enteroscope with SBE. During the reduction maneuver with SBE, the overtube balloon is inflated and the distal end of the enteroscope hooked over a fold as the SBE does not have a distal balloon.

Even the dimensions of the enteroscope and the overtubes are virtually identical to those of DBE. The overtube balloon is made of a silicone material rather than latex. SBEs have a stiff shaft and the enteroscope can be easily removed and reinserted through the overtube. Its caliber is similar to that of a standard upper endoscope but with more than twice its length (200 cm). Hence, most endoscopic diagnostic and therapeutic maneuvers are possible to perform with the SBEs.

A preliminary report of 78 SBE procedures performed in 41 patients, of whom 12 had small bowel bleeding, found that SBE allowed evaluation of the SB in a safe and effective manner, including performance of total enteroscopy (25%; 6/24). The diagnostic yield in patients with suspected small bowel bleeding sources was 33% (4/12 patients), and therapeutics such as argon plasma coagulation could be successfully performed (20). Another study evaluated 20 patients with suspected SB disorders, and found a diagnostic yield of 60% using SBE (101). More recent studies have found diagnostic yields between 65 and 74% (102–104). SBE also appears to be associated with improved outcomes (105). A prospective study on 105 patients who underwent at least one oral SBE procedure found no complications related to the diagnostic procedures (106). One perforation occurred after stricture dilation. Prospective, sequential amylase testing before and after SBE showed 16% of patients developed elevation of serum amylase but without any overt clinical evidence of acute pancreatitis. At this time, it appears that SBE is equivalent to DBE for the evaluation of small bowel bleeding sources (107,108).

### Spiral enteroscopy

Spiral enteroscopy consists of a unique overtube with an outer raised spiral ridge at its distal end through which an SBE or a DBE can be inserted. It is used for enteroscopy via the oral route and can be used only with enteroscopes <9.4 mm in diameter. Unlike the balloon enteroscopy techniques, spiral enteroscopy uses the clockwise motion of the ridged overtube to draw the enteroscope forward. It is a two-person procedure, with a nurse or physician rotating the overtube while the endoscopist is keeping the lumen of the SB in view. The duodenojejunal transition poses a technical challenge because of the sharp angulation that may prevent the overtube from safely engaging the proximal jejunum for forward passage. Aside from that, the procedure is rather simple to perform and forward progress can complete in about 18 min (109). Based on the prior literature, the mean ( $\pm$ s.d.) procedure times for the antegrade approach have been estimated to be 79 $\pm$ 15 min for DBE (10 studies) (51,82–84,87,110–114), 65 $\pm$ 16 min for SBE (5 studies) (20,106,115–117), and 35 $\pm$ 6 min for spiral enteroscopy (4 trials) (109,118–120). Even though most experts assume that this technique covers less ground than DBE, there is one case described in a letter to the editors in which an orally passed spiral enteroscope reached the cecum in 65 min (121). The diagnostic



yield of the initial cases of spiral enteroscopy has been reported to be only 33% (122). Since that time, a more recent prospective study suggested that the diagnostic yield in patients with a positive capsule study was 57% (119). Furthermore, a prospective cohort study also found that spiral enteroscopy leads to improved outcomes in terms of transfusion requirements, iron supplementation, and additional therapeutic procedures (123). There is also an overtube for a rectal approach that can be used for limited ileoscopy. Questions have been raised about some safety concerns with regards to bowel trauma and difficulty in rapid removal during an emergency. However, there had been no major complication reported in the early literature (120). In a series of 75 patients, 12% of had a sore throat, 27% had superficial mucosal trauma, and 7% had moderate esophageal trauma that did not require any intervention. In a retrospective registry study involving 1750 patients, the rate of severe complications was reported to be 0.34%, with a small bowel perforation rate of 0.27% (118). In the first 850 cases reported in the literature with spiral enteroscopy, there were no serious complications (124).

#### Intraoperative enteroscopy

IOE involves evaluation of the SB at laparotomy, and may be performed orally, rectally, or via an enterotomy, wherein the scope is inserted through a surgical incision in the SB (125). Upper endoscopes, colonoscopes, push enteroscopes, and the newer balloon-assisted scopes have all been used in IOE. This may be the most reliable method to achieve a complete small bowel evaluation but it is highly invasive. Although the diagnostic yield of IOE has been reported to range from 58 to 88% (126), rebleeding may occur in up to 60% of patients (127–130). Major complications of IOE include serosal tears, avulsion of mesenteric vessels, and prolonged ileus (130). In addition, the procedure has a high mortality rate of 17%. Owing to these reasons, IOE should be reserved only for those patients who present with recurrent bleeds requiring multiple transfusions or hospitalizations after a comprehensive negative evaluation with VCE and deep enteroscopy or for patients in whom deep enteroscopy cannot be performed without lysis of adhesions (131).

#### Comparison of endoscopic modalities in suspected small bowel bleeding

**Capsule endoscopy compared with push enteroscopy and small bowel follow-through.** Multiple retrospective and prospective studies have found VCE to be superior to both push enteroscopy and small bowel series in the evaluation of patients with suspected small bowel bleeding. A meta-analysis of studies that compared VCE and push enteroscopy showed that VCE had an incremental yield of 30% (yield 56% vs. 26%) for clinically significant findings in patients with small bowel bleeding sources. Similarly, VCE had an incremental yield of 36% over small bowel series (yield 42% vs. 6%) (132). The number needed to test with VCE was three, to establish one additional diagnosis. Based on subanalysis of the data, VCE had a higher yield for both vascular and inflammatory lesions. VCE has hence largely replaced push enteroscopy and small bowel series in the evaluation of the SB, and is currently

recommended as the third test of choice in patients with suspected small bowel bleeding, who have had a negative esophagogastroduodenoscopy and colonoscopy.

**DBE compared with push enteroscopy and VCE.** A study by May *et al.* (85), which compared DBE to push enteroscopy in 52 patients with suspected small bowel bleeding, found that DBE not only allowed a greater depth of intubation (230 vs. 80 cm) but also had a higher yield for small bowel findings (73% vs. 44%). Furthermore, DBE facilitated detection of additional lesions in the distal small bowel in patients who had positive findings on push enteroscopy.

Several studies have compared the yield of VCE with DBE, but have shown inconsistent results because of their small sample size. A meta-analysis of 11 studies that compared these modalities in patients with SB disease (majority with suspected small bowel bleeding) showed a comparable diagnostic yield (60% vs. 57%; incremental yield of 3%) for all SB findings. The yield with the tests was also similar for vascular, inflammatory, and neoplastic lesions (4). Another meta-analysis of eight studies also found no difference in diagnostic yield between the two tests for the evaluation of SB disease (odds ratio 1.21, 95% confidence interval (CI): 0.64–2.29)). In patients with small bowel bleeding, VCE had a higher yield as compared with DBE using a single approach (odds ratio 1.61, 95% CI: 1.07–2.43), but a significantly lower yield as compared with DBE using a combined antegrade and retrograde approach (odds ratio 0.12, 95% CI: 0.03–0.52) (133). This finding reinforces the importance of total enteroscopy with DBE in patients with high clinical suspicion for an SB lesion. Another meta-analysis similarly showed comparable diagnostic yields, and also suggested that the diagnostic yield improves if performed in patients with a positive capsule study (134). Two more recent meta-analyses again confirm the similarity in diagnostic yields between VCE and DBE (89,135).

VCE has been reported to be useful as a screening tool before DBE in patients with suspected small bowel bleeding. This approach of a ‘targeted DBE’ has been reported to increase both the diagnostic (73–93%) and therapeutic yield (57–73%) of the test (136). Furthermore, VCE transit times have been found useful in guiding the optimal route of DBE. Owing to deeper intubation of the small bowel and a higher success rate with the oral approach, this is the preferred route for lesions suspected to lie within the proximal 75% of the small bowel, whereas the rectal route is used for more distal lesions. Because of the high negative predictive value of VCE, the approach of VCE-guided DBE allows avoidance of DBE in patients with a low pretest probability for SB findings (137–139).

However, the concept of CE-guided DBE may not be applicable in all patients. VCE has a false-negative rate of 11% for all SB findings, and more importantly, up to 19% for neoplasms. Additional findings on repeat VCE have been detected in up to 75% of patients with suspected small bowel bleeding, thereby leading to a change in management in 62% (69). There have also been reports of neoplasms missed on VCE and subsequently diagnosed at DBE (140). Hence, in patients with a negative VCE, in whom there is a high clinical suspicion for an SB lesion, DBE should still be pursued, including consideration for total enteroscopy (4).

The indications for DBE in patients with suspected small bowel bleeding is broad, and include patients who have a positive VCE, both for tissue diagnosis and therapeutics; patients in whom VCE is contraindicated; patients with a negative VCE, but high clinical suspicion for SB lesion; and in patients with active bleeding.

**Spiral enteroscopy compared with DBE.** In a small prospective, cross-over, single-center trial comparing oral DBE to spiral enteroscopy in patients with suspected small bowel vascular malformations, the mean insertion time was significantly quicker for spiral enteroscopy (43 vs. 65 min;  $P=0.007$ ). However, more importantly, the depth of insertion was significantly greater for DBE (310 vs. 250 cm;  $P=0.004$ ) (141). A more recent prospective study found them to be similar in terms of insertion time and distance, as well as of diagnostic and therapeutic yield (142).

**Cost-effectiveness analysis.** A cost-effectiveness analysis that compared various diagnostic modalities (push enteroscopy, DBE, VCE-guided DBE, angiography, and IOE) found that DBE was not only the most cost-effective approach in the evaluation of overt small bowel bleeding but also had the highest success rate for bleeding cessation. However, the investigators concluded that VCE-guided DBE may be associated with better long-term outcomes as compared with the initial DBE approach, because of decreased risk for complications and appropriate utilization of endoscopic resources (143).

### Diagnosis using radiographic techniques

#### Recommendations

1. Barium studies should not be performed in the evaluation of small bowel bleeding (strong recommendation, high level evidence).
2. CTE should be performed in patients with suspected small bowel bleeding and negative capsule endoscopy because of higher sensitivity for the detection of mural-based small bowel masses, superior capability to locate small bowel masses, and ability to guide subsequent deep enteroscopy. (strong recommendation, low level of evidence).
3. CT is preferred over MR imaging for the evaluation of suspected small bowel bleeding. MR can be considered in patients with contraindications for CT or to avoid radiation exposure in younger patients (conditional recommendation, very low level of evidence).
4. CTE could be considered before VCE in the setting of established inflammatory bowel disease, prior radiation therapy, previous small bowel surgery, and/or suspected small bowel stenosis (strong recommendation, very low level of evidence).
5. In patients with suspected small bowel bleeding and negative VCE examination, CTE should be performed if there is high clinical suspicion for a small bowel source despite the performance of a prior standard CT of the abdomen (conditional recommendation, very low level of evidence).

**Usage of abdominal imaging.** As mentioned previously, barium examinations of the small bowel have had low yields (3–17%) for detecting abnormalities in the setting of suspected small bowel bleeding (132,144–146), and therefore are not recommended in the evaluation of patients with suspected small bowel bleeding.

Cross-sectional imaging techniques optimized for imaging the small bowel have a larger role in small bowel imaging and have shown improved performance over routine CT (147). Advantages of these techniques include the ability to see all bowel loops without superimposition and the visualization of extraluminal structures (148,149). Imaging can be performed using either enterography technique, which requires ingestion of large volumes of contrast medium, or enteroclysis with direct administration of enteric fluid by a nasoenteric tube. Enteroclysis provides superior small bowel distension; however, it is not as well tolerated or widely used (150). The fluid administered should be a neutral contrast or near water density to improve detection of hyperenhancing abnormalities or bleeding. These optimized small bowel techniques can be performed using CT or MR. CT is more widely used in the setting of GI bleeding because of the superior temporal and spatial resolution compared with MR and is more widely available. Images obtained during multiple phases of enhancement likely improves detection and characterization of the site and cause of GI bleeding (151–156). Overt bleeding can be detected using multiphasic CT without enterography technique (CT angiography (CTA)). Patients with overt bleeding may not be able to drink oral contrast or may be hemodynamically unstable. In addition, the oral contrast may dilute the contrast extravasation and make subtle active bleeding more difficult to detect. In stable patients with suspected small bowel bleeding, enterography with enteric contrast improves detection of intraluminal masses, which may be the cause of bleeding.

Multiple studies have demonstrated that the yields for imaging techniques are higher in the setting of overt bleeding compared with patients with occult bleeding (151,156–159).

**CT enterography.** In a meta-analysis of 18 studies, CTE had a pooled yield of 40% compared with 53% for VCE (160). Other studies have shown similar yields for CTE (151,156,158,159).

Several studies have shown that VCE has higher yields for detecting vascular and inflammatory lesion compared with CTE (144,160,161). However, some studies have shown that CTE can detect vascular and inflammatory abnormalities, which may be missed on VCE (154). The detection of subtle vascular abnormalities at CTE may be influenced by technique and experience.

An advantage of CTE over VCE is the improved detection of small bowel masses, especially those that are mural-based. In a study by Huprich *et al.* (154), CTE detected 9/9 small bowel tumors, whereas VCE only detected 3/9 of the lesions.

Therefore, CTE and VCE are complementary examinations. In a study of 30 patients with negative CTE, subsequent VCE was positive in 57% (161). In another study of 52 patients with non-diagnostic VCE, subsequent CTE had a 50% positive yield in those patients with overt small bowel bleeding (151). Because of the

small number of studies regarding MR enterography (150,162), this exam is not routinely recommended *in lieu* of CTE, but can be considered in patients aged <40 years because of lower radiation exposure.

Compared with cross-sectional imaging studies, VCE is uniformly superior for demonstration of vascular abnormalities (144,146,149,150,162,163), whereas cross-sectional imaging can identify masses (146,150,163) and some inflammatory changes (150) missed at VCE.

Another advantage of cross-sectional small bowel imaging techniques is the ability to screen for contraindications to capsule endoscopy. In one study, 11% of patients being evaluated for suspected small bowel bleeding were excluded from VCE secondary to high-grade strictures identified on MR enterography (150).

### Overt acute GI bleeding (Figures 2–3)

#### Recommendations

1. In acute overt massive GI bleeding, conventional angiography should be performed emergently for hemodynamically unstable patients (strong recommendation, low level of evidence).
2. In hemodynamically stable patients with evidence of active bleeding, multiphasic CT (CTA) can be performed to identify the site of bleeding and guide further management (strong recommendation, low level of evidence).
3. In patients with acute overt GI bleeding and slower rates of bleeding (0.1–0.2 ml/min), or uncertainty if actively bleeding, tagged red blood cell (RBC) scintigraphy should be performed if deep enteroscopy or VCE are not performed to guide timing of angiography (strong recommendation, moderate level of evidence).
4. In brisk active overt bleeding, CTA is preferred over CTE (conditional recommendation, very low level of evidence).
5. Conventional angiography should not be performed as a diagnostic test in patients without overt bleeding (conditional recommendation, very low level of evidence).
6. Provocative angiography can be considered in the setting of ongoing overt bleeding and negative VCE, deep enteroscopy, and/or CT examination (conditional recommendation, very low level of evidence).
7. In younger patients with ongoing overt bleeding and normal testing with VCE and enterography examinations, a Meckel's scan should be performed (conditional recommendation, very low level of evidence).

#### Radiographic diagnosis for overt GI bleeding

Historically the radiologic diagnosis for acute overt GI bleeding has been performed using Technetium 99m-labeled ( $^{99m}\text{Tc}$ ) RBC scintigraphy and conventional angiography. Promising initial results have led to increasing utilization of CTA. Given that the small bowel is the source of GI bleeding only in a minority of cases, most reported studies on  $^{99m}\text{Tc}$ -labeled RBC scintigraphy, conventional angiography, and CTA have included upper GI, small bowel, and colonic data.

#### CT angiography

Most studies using CT to evaluate GI bleeding are performed during multiple phases of contrast enhancement with one of the phases occurring during the arterial phase of enhancement. When performed with oral contrast, this is referred to as multiphasic CTE. When no oral contrast is administered, the technique has been termed multiphasic CT or CTA. Multiphasic CT or CTA is usually performed to detect the site of active bleeding in cases of acute overt bleeding, which can occur sporadically or in the setting of small bowel bleeding. CTA has been shown to be able to detect bleeding rates as slow as 0.3 ml/min compared with 0.5–1.0 ml/min for conventional angiography and 0.2 ml/min for  $^{99m}\text{Tc}$  tagged RBC scintigraphy.

A meta-analysis of 9 studies with 198 patients showed CTA had a pooled sensitivity of 89% and specificity of 85% in diagnosing acute GI bleeding throughout the GI tract (164). Several of these studies showed detection by CTA which were negative by other techniques. CT is widely available and can be performed rapidly during the time of bleeding, which may aid in detection compared with other techniques. CT has also been shown to localize accurately the site of bleeding (165). Other studies have shown sensitivities of 79–94% and specificity of 95–100% for detecting active bleeding throughout the GI tract (165–167). In a study of 113 consecutive patients with active GI bleeding, CTA was positive in 80/113 (70.8%), all of which were confirmed. Negative studies were seen in 33 patients (29.2%). Out of 33, 27 of these negative cases did not require further intervention (168).

In a retrospective analysis of 31 patients with overt suspected small bowel bleeding, CT had a yield of 45% (86% tumor yield and 33% non-tumor yield) compared with 94% for double-balloon endoscopy. CT detected 1 of 7 ulcers, 6 of 7 tumors, and both angiodysplasias seen at DBE. In addition, CT was able to provide correct guidance for DBE in 100% of cases (169).

CTA can also be used to help triage patients for further management. In one study, 64/86 CT angiograms were negative and 92% of these patients required no further intervention. There were no cases with a negative CTA that had a subsequent positive conventional angiogram within 24 h (166). Therefore, some have recommended watchful waiting in cases with a negative CTA as the bleeding rate may be low or intermittent and conventional angiography rarely shows an additional site of bleeding. Factors predictive for a positive conventional angiogram following a positive CTA include non-diverticular etiologies and lower hemoglobin levels and should be performed soon after the CTA to enhance detection (170).

CTA has some limitations however. To detect contrast extravasation, the patient must be actively bleeding at the time of the scan. The findings of blood within the lumen or sentinel clot may help to localize the source if the bleeding is subtle or absent. If no active bleeding or source is identified at the time of the CTA additional workup may be necessary. In elderly patients with decreased renal function, the administration of the intravenous contrast for CT may increase the risk of renal complications if subsequent conventional angiography is required.

### Scintigraphy

<sup>99m</sup>Tc-labeled RBC scintigraphy has been used in the evaluation of overt acute GI bleeding for many years. Advantages of scintigraphy include the ability to detect lower rates of bleeding and the ability to perform delayed imaging that can improve detection of intermittent or delayed bleeding (171). Detection of bleeding at angiography may be enhanced by timing the angiogram to evidence of active bleeding at scintigraphy. Therefore, the examination must be closely monitored so that the patient can be taken quickly to angiography. Limitations of scintigraphy include the reported variability in localization of bleeding, which may be more difficult in the foregut and small bowel (172), and the inability to characterize the source of bleeding.

There is a wide range of reported sensitivities (33–93%), specificity (30–95%), diagnostic yields (26–87%), and localization accuracy (19–100%) for scintigraphy throughout the GI tract (164,171–180). Because bleeding is intermittent, scintigraphy may be helpful in identifying the site of bleeding when other diagnostic tests have been negative (180–182).

Negative scintigraphy may also be an indicator of better outcomes (175). In some studies, many of the patients with negative scans may stop bleeding spontaneously and need no further treatment, whereas those with positive scans may need intervention (175,176).

Because of the large variations in the reported diagnostic yield, sensitivity, accuracy in localization, and correlation of outcomes combined with the inability to characterize the source of bleeding, there is considerable controversy on the use of scintigraphy for acute overt GI bleeding (183).

In younger patients with ongoing overt bleeding and negative evaluation with VCE, CTE, or other testing modalities, consideration should be made for testing with a <sup>99m</sup>Tc-pertechnetate scan for detection of Meckel's diverticulum (184). Ectopic gastric mucosa can be seen in 10–60% of Meckel's diverticulae (172,185). The results of <sup>99m</sup>Tc-labeled pertechnetate scans can be varied and are dependent on the quantity and functional quality of the heterotopic gastric mucosa (186). The diagnostic yields from these scans appear to be highest when performed in children. Sensitivities have ranged from 50 to 90% with specificities from 9 to 95% (172,185–187). There are several false positives that occur related to uptake in ulcers, inflammatory lesion, arteriovenous malformations, obstruction, intussusceptions, and ectopic gastric mucosa in other lesions such as duplication cysts (172,185). False negatives can occur with anatomic or physiologic cause or other inflammation such as ectopic pancreatic mucosa, which can be present in up to 74% of diverticula (186).

### Angiography

As with scintigraphy, conventional angiography has been used for many years in patients with active GI bleeding, especially in those who may be more hemodynamically unstable. An advantage of angiography is the ability to perform therapeutic intervention with transarterial embolization at the time of diagnosis and angiography is not hampered by impaired visualization of the source

by intraluminal blood. Limitations of angiography include the need for higher rates of bleeding (0.5–1.0 ml/min) for detection and the risk of complications (including renal failure, thromboembolic events, and more commonly infections or bleeding at the catheter site) that can occur in up to 10% (183,188). Data from multiple studies assessing results throughout the GI tract show yields for angiography in the range of 20–77% with a mean near 50% (181,182,189–191).

Predictors of positive angiography include hemodynamic instability, particularly in those who require transfusion of  $\geq 5$  U to achieve hemodynamic stability (191). A positive yield was shown to increase to 87% with more massive GI bleeding. Angiographic yields are highest when the patient is actively bleeding with minimal delay from presentation (192).

Patients with a negative tagged RBC scan implying a slow bleeding rate or a negative CT angiogram are unlikely to have a positive conventional angiogram (166). In patients with a positive CT angiogram, those with non-diverticular etiologies and lower hemoglobin were more likely to have a subsequent positive conventional angiogram (170).

For small vascular abnormalities that require surgical intervention, placement of a catheter in the vessel supplying the vascular abnormality and dye staining can assist with intraoperative localization.

Previously, provocative angiography using hemodilution agents, vasodilators, anticoagulants, and thrombolytics has been performed in cases of GI bleeding with normal conventional angiography with good results and low complications rates (193). However, because of varied results in clinical practice and newer sensitive techniques, provocative angiography is rarely used today. Provocative angiography may be considered when all other diagnostic techniques have been unrevealing.

### Treatment with angiography

Throughout the years, catheter-based intervention has shown significant advances with transition from vasopressin infusion to superselective transarterial embolization, resulting in improved results and decreased complications. In 15 studies from 1992 to 2006, consisting of 309 patients and using superselective transarterial embolization, there was an 82% success rate, 95% overall clinical success rate, 76% 30-day success rate, and rebleed rate of 12% (194). However, the majority of these cases were performed for bleeding sources outside of the small bowel.

In a recent retrospective study of 70 patients, Hongsakul *et al.* (195) had a 99% technical success rate, 71% primary clinical success rate, and 79% secondary clinical success rate after repeat embolization. Bowel infarction was seen in 4%, with the majority of the cases involving bleeding sources outside of the small bowel. Predictors of failure to achieve 30-day hemostasis include hemoglobin  $< 8$  g/dl, coagulopathy and upper GIB, contrast extravasation, and more than one vessel embolized.

In a retrospective review of 107 angiograms during 83 episodes of bleeding, angiography effectively identified the site of bleeding

in 48% of patients and allowed embolization in 45%. Embolization achieved clinical success in 76% of patients but repeat embolization was associated with a high rate of complications. The overall mortality was 7%, with four deaths because of rebleeding and two deaths because of a medical comorbidity (190).

## Treatment and outcomes

### Recommendations

1. If a source of bleeding is found by VCE and/or deep enteroscopy in the small intestine that is associated with significant ongoing anemia or active bleeding, then the patient should be managed with endoscopic therapy (strong recommendation, low level of evidence).
2. If after appropriate small bowel investigation no source of bleeding is found, the patient should be managed conservatively with oral iron or by intravenous infusion as is dictated by the severity and persistence of the associated iron-deficiency anemia. In this context, a small vascular lesion found on capsule endoscopy does not always need treatment (strong recommendation, very low level evidence).
3. If bleeding persists in either of the above situations with worsening anemia, a further diagnostic workup should include a repeated upper and lower endoscopy, VCE, deep enteroscopy, CT, or MRI enterography as is appropriate for the clinical situation and availability of investigative devices (strong recommendation, low level evidence).
4. If bleeding persists or recurs or a lesion cannot be localized consideration may be given to medical treatment with iron, somostatin analogs, or antiangiogenic therapy (strong recommendation, moderate level evidence).
5. Anticoagulation and/or antiplatelet therapy should be discontinued if possible in patients with small bowel hemorrhage (conditional recommendation, very low level evidence).
6. Surgical intervention in massive small bowel bleeding may be useful, but is greatly aided with presurgical localization of the bleeding site by marking the lesion with a tattoo (strong recommendation, low level evidence).
7. IOE should be available at the time of the surgical procedure to provide assistance to localize the source of bleeding and to perform endoscopic therapy (conditional recommendation, low level of evidence).
8. Patients with Heyde's syndrome (aortic stenosis and angioectasia) and ongoing bleeding should undergo aortic valve replacement (conditional recommendation, moderate level of evidence).
9. For patients with recurrence of small bowel bleeding, endoscopic management can be considered depending on the patient's clinical course and response to prior therapy (conditional recommendation, moderate level of evidence).

This section will focus primarily on the treatment of vascular abnormalities in the small intestine. The treatment of bleeding from Crohn's disease, polyposis syndromes, and small intestinal neoplasms is beyond the scope of this guideline.

### Treatment of small bowel vascular lesions

Evidence from randomized controlled clinical trials as to how best to treat small bowel bleeding has been very limited. Data from the precapsule era on angioectasias found in the stomach and colon demonstrated that non-bleeding lesions were not treated, whereas those actively bleeding were treated endoscopically (196). Angioectasias in the stomach and colon may be markers for small bowel angioectasia. Despite endoscopic therapy, the recurrence rate after treatment of vascular lesions has ranged from 20 to nearly 50%.

### Endoscopic therapy

Data regarding efficacy of endoscopic therapy for small bowel vascular lesions were limited to studies using push enteroscopy and surgical intervention before 2001. Despite ongoing usage of push enteroscopy with heater probe therapy (197,198) and introduction of deep enteroscopy after 2004, rebleeding rates from vascular lesions have not declined significantly. In the era before deep enteroscopy, most angioectasia in the stomach and/or colon were treated with tools including monopolar and bipolar probes that provided electrocoagulation, or neodymium yttrium-aluminum-Garnet laser that provided tissue coagulation. Since 2001, argon plasma coagulation has been primarily used as the treatment of choice.

As a general statement, the outcomes associated with treatment of small bowel sources of bleeding have been disappointing and there has been a paucity of data regarding outcomes after treatment of small bowel angioectasia. To date, there have not been any published trials comparing endoscopic therapy of angioectasia compared with sham therapy or trials where only actively bleeding lesions or lesions of a certain size are treated compared with therapy for all visualized lesions. Given these limitations, recurrence of bleeding has been used as a surrogate as to the effectiveness of treatment. Even this strategy is limited because we know little of whether there are subsets of vascular lesions in the small intestine that do benefit from therapy. Two randomized controlled studies demonstrated lack of benefit of either intervention, VCE vs. radiology (199), or by hormonal therapy (200) compared with placebo. The placebo arm in both studies demonstrated the natural history of bleeding from angioectasia. In the radiology study vs. VCE, the rebleeding rate was 30% in those studied by capsule vs. 24% investigated by radiology, a nonsignificant difference. Similarly, the rebleeding rate in the study using hormonal therapy vs. placebo showed a nonsignificant 7% difference after a mean of 412 days of follow-up.

There have been several studies looking at the recurrence of bleeding after endoscopic treatment of vascular lesions in the small intestine as a measure of its effectiveness. The most recent was of a retrospective cohort study carried out at a French tertiary-referral center between January 2004 and December 2007. Of 261 patients who presented with suspected small bowel bleeding, 129 of 133 (97%) patients with small bowel vascular lesions were successfully treated with argon plasma coagulation (using DBE). At 36 months, rebleeding occurred in 45/98 (46%) patients (201). A second study involved 274 patients who had undergone DBE at two different

centers between 2004 and 2006 (14). At 12 months, 43% of 101 patients reported no further overt bleeding, 23% reported recurrent overt bleeding, and 35% reported ongoing iron and/or transfusion requirements. Of the 85 patients who were interviewed at a mean of 30 months, 50 (59%) reported no overt bleeding or iron/transfusion needs, 20 (24%) reported further overt bleeding, and 15 (18%) reported ongoing iron and transfusion requirements. A recent meta-analysis of 14 studies including 623 subjects with small bowel angioectasia treated with endoscopic therapy demonstrated a pooled rebleeding rate of 34% (95% CI: 27–42%) after a mean of 22±13 months. This rebleeding rate increased to 45% when the 341 patients with small bowel angioectasia were analyzed (202).

Risk factors for recurrent bleeding from small bowel angioectasia have included the number of vascular lesions (13,201,203), age over 65 years (204,205), presence of lesions in the jejunum (205), presence of cardiac valvular disease (65,201), chronic renal disease (65,204,206), usage of anticoagulant medication (47), and need for transfusion.

Heyde's syndrome is a controversial association between the presence of aortic stenosis and angioectasia, thought to be secondary to an acquired type 2 von Willebrand deficiency (207,208). In support of this relationship is the fact that some patients with aortic stenosis have demonstrated resolution of GIB after aortic valve replacement (202). Patients with left ventricular assist devices have also been demonstrated to be at risk for angioectasia and recurrent bleeding, again secondary to an acquired von-Willebrand deficiency syndrome (209). Pilot studies have demonstrated that decreased levels of von Willebrand factor are predictive of recurrent bleeding from small bowel angioectasia in patients with left ventricular assist devices (210).

### Medical treatment of small bowel bleeding

Supportive care with iron given orally or intravenously is a mainstay of treatment for mild small intestinal bleeding (211). This not only helps maintain an adequate level of hemoglobin, but in more severe cases help reduce the frequency of transfusion. In more severe bleeding, transfusion of packed RBCs is an essential element of treatment, particularly when mechanistic and medical methods fail.

Although anticoagulation has been associated with an increased risk of recurrent bleeding (47), there is no prospective data showing that withdrawal of anticoagulation therapy is beneficial. In a 2009 assessing 162 patients with small bowel bleeding, risk factors for recurrent bleeding after DBE included the presence of small bowel vascular disorders and comorbid conditions, but not the usage of anticoagulants or antiplatelet therapy (65). Another follow-up study in 2010 demonstrated that transfusional requirements, number, and type of vascular lesions were predictors for recurrent bleeding, but not anticoagulant usage (212). There is no data that cessation of antiplatelet therapy reduces the risk for recurrent bleeding.

Specific medical treatment for small bowel bleeding is poorly developed. Hormonal therapy has not been shown to be helpful. Thalidomide and octreotide have been shown to have some benefit.

### Hormonal therapy

There have been several trials of hormonal therapy, all in the pre-capsule era. Thus, the precise nature of what was treated was largely unknown with respect to the small intestine. The proposed mechanism of action for these agents included shortening of the bleeding time contributing to an effect on hemostasis (213). However, other studies suggested that these agents may instead increase plasma fibrinolysis and lead to recurrent bleeding (214). A prospective randomized double-blind placebo-controlled crossover study performed in Belgium in 1990 created enthusiasm for hormonal treatment. This was a small study with 10 patients; it demonstrated a 78% reduction in transfusion in the patient's treated with ethinyl estradiol 50µg and norethisterone 1 mg daily for 6 months compared with those treated with placebo. Only one patient on the drug required transfusion compared with all on the placebo. The majority of patients had chronic renal failure or von Willebrand's disease (215), factors that may not be representative of typical angioectasia patients. A multicenter double-blind randomized study, in Spain, of the use of hormonal therapy vs. placebo in patients with GI angioectasia, showed no benefit after a year of treatment. The hormonal therapy used was ethinyl estradiol 0.01 mg plus norethisterone 2.0 mg or placebo daily for at least 1 year. There were 35 patients in the placebo group and 33 in the treatment group. Failure rates for the treatment and placebo groups were 39% and 46%, respectively, a nonsignificant difference (200,216). There was no difference in the number of bleeding episodes or transfusion requirements over a mean period of 412±255 days (range 1–3 years). Serious adverse event occurred in both groups—one pulmonary thromboembolic event in each group. One patient died of an ischemic stroke in the placebo group and there was one stroke in the treatment group. One-third of the women in the treatment group had menorrhagia in response to the hormonal treatment.

In an earlier study by Lewis *et al.* (217), 30 of 64 patients with small bowel angioectasia received 5–10 mg of norethynodrel either with mestranol 0.075–0.15 mg 24 patients or in conjunction with conjugated estrogens 0.625 mg (six patients), whereas the other half of the cohort did not receive any further treatment. In the untreated group, 15 of 34 (44%) required no further therapy compared with 15 of 30 (50%) of the treated group of a mean of 16 months ( $p=0.8$ ). In summary, hormonal therapy does not appear to have a role in the treatment of small bowel bleeding.

### Somatostatin analogs

Interest in the use of somatostatin analogs for treating angioectasia started in 1999 (216). The proposed mechanism of action for these agents has included reduction of bleeding by the inhibition of angiogenesis, decrease in splanchnic flow, increase in vascular resistance, and improved platelet aggregation (218). A number of case reports were followed by a systematic review in 2010 (219) demonstrating a significant reduction in the need for blood products in 62 patients from three small studies. Following this systematic review, Bon *et al.* (220) reported response rates for a further 15 patients with angiodysplasias in the stomach ( $n=6$ ), small intestine ( $n=9$ ), and colon ( $n=3$ ). These

were consecutive patients who had been bleeding for at least 6 months and had endoscopic evaluation with upper endoscopy, colonoscopy, and VCE, radiological examination with abdominal CT, and, in some cases, DBE. Most had comorbid diseases listed by Nardone *et al.* (216) as independent co-factors for rebleeding and some were on anticoagulation. Those with refractory bleeding, defined as patients requiring >5 U of blood within 3 months after conventional treatment, were given depot octreotide LAR intramuscularly monthly or Lanreotide 90 mg monthly for a mean of 12 months (range 6–36 months). Transfusion requirements during treatment decreased to 2 (range 0–14) vs. 10 (6–24) in the period before treatment ( $P<0.001$ ). The number of patients experiencing a bleeding episode also decreased to 20% in the treatment group compared with 73% in the pretreatment phase ( $p=0.001$ ).

Most recently, Nardone *et al.* (221) performed a retrospective analysis of the use of octreotide in 98 patients. The investigators demonstrated a reduction of transfusion requirements over a mean follow-up period of 78 months. Forty percent were categorized as complete responders, 32% were partial responders, and 26% were non-responders. The protocol used octreotide 100 µg (three times a day) subcutaneously for 1 month; at 2 weeks, patients received an injection of depot preparation of 20 mg monthly for 6 months. Multivariate analysis showed age over 65 years, male gender, use of antiplatelet therapy, and the presence of chronic obstructive pulmonary disease or chronic renal failure were independent predictors of poor outcome. In summary, a recent meta-analysis confirms the value of octreotide and its analogs but provides no support for hormonal treatment (202).

### Thalidomide

Thalidomide, a drug with a tragic past, has made a resurgence owing to its properties as an antiangiogenic agent, possibly by its inhibition by vascular endothelial growth factor (222). It is also an antitumor necrosis factor agent and an immune modulator.

There have been several small case studies and one good sized randomized open-label controlled trial that included a variety of vascular malformations throughout the GI tract, but predominantly in the small intestine (223). Patients enrolled in the randomized open-label controlled trial were required to have at least six or more bleeding episodes (measured by positive immunoassay fecal occult blood test) and received either 25 mg (four times a day) of thalidomide or 100 mg of iron daily for 4 months, with at least a 12-month follow-up. The primary end point, defined as the proportion of patients showing a reduction of bleeding episodes by  $\geq 50\%$ , was met in 20/28 (71%) of patients on thalidomide compared with 1/27 (4%) of those on iron supplementation ( $p<0.001$ ). Adverse events including fatigue, constipation, and somnolence were reported by 73% of the thalidomide group and 34% of the iron cohort. Levels of vascular endothelial growth factor were consistently and significantly lower in the thalidomide group.

The benefit of thalidomide for patients with small bowel angiodysplasia failing endoscopic therapy was demonstrated in 9/12 (75%) patients in a study published in 2012 where patients received daily doses of 200 mg for 4 months (224). The mean hemoglobin

concentration before treatment was 6.5 g/dl and at the end of treatment was 12.1 g/dl. Three patients were withdrawn from the study because of adverse side effects.

### Radiological treatment

This modality is covered in the section on radiological diagnosis.

### Surgical treatment

Surgical treatment for small intestinal bleeding is generally regarded as a last resort or for patients requiring lysis of adhesions in order to perform successful deep enteroscopy. In the pre-enteroscopic era, a right hemicolectomy was performed as the treatment of choice for recurrent GI bleeding, presumed to originate from right-sided diverticulosis as the source of bleeding (225). Subsequently, surgical treatment of small intestinal bleeding has been guided by IOE where possible or by a combination of VCE deep enteroscopy and/or angiographic techniques (129,226). In a report by Hartmann *et al.* (226), 47 consecutive patients with suspected small bowel bleeding had a negative conventional work-up followed by VCE studies. These patients then underwent IOE via an enterotomy; the endoscopist was blind to the results of the prior VCE study. A bleeding source was identified on IOE in 73% of all cases. Diagnostic yields were 100% for patients with ongoing overt bleeding, 70% in overt previous bleeding, and 50% in occult bleeding with an overall mortality rate of 2%. An interesting combined radiological and surgical option has been recently re-reported involving angiographic localization of small bowel vascular lesions (227). The angiographic catheter is left in place and the patient is transferred to the operating room. At laparotomy, methylene blue is injected via the angiographic catheter. The dye highlights the vasculature and mesentery related to the intestinal lesion, making it easy for the surgeon to resect the relevant segment of small intestine. Surgery displays excellent results with discrete lesions such as tumors or localized arteriovascular malformations. More diffuse lesions, such as multiple angiodysplasias, are usually treated endoscopically at the time of operation. As the treatment is the same as that delivered at deep or push enteroscopy, rebleeding rates can be anticipated to be similar, but there is no long-term follow-up data.

For patients with Heyde's syndrome (aortic stenosis and angiodysplasia), a recent meta-analysis suggested a reduced bleeding risk after aortic valve replacement based on data from two studies (pooled event rate of 0.16 for rebleeding events (95% CI: 0.05–0.38)).(202)

### CONCLUSION

The occurrence of small bowel bleeding remains a relatively uncommon event. A significant percentage of patients with suspected small bowel bleeding will have sources of bleeding detected upon repeat upper and lower endoscopic examinations. The remainder of the patients will likely demonstrate sources of bleeding in the small bowel on VCE, deep enteroscopy or CTE studies. Given the efficacy of these new imaging modalities, the prior classification of "obscure GI bleeding" should be reserved

for patients in whom a bleeding source cannot be demonstrated after an extensive evaluation. Small bowel angiodysplastic lesions remain the most common cause of small bowel bleeding, and despite endoscopic therapy, demonstrate high recurrence rates. Medical therapy with somatostatin analogs or antiangiogenic agents may be an option for refractory patients. Surgical therapy should be reserved for patients requiring lysis of adhesions for successful deep enteroscopy, and aortic valve replacement should be considered for patients with Heyde's syndrome.

#### CONFLICT OF INTEREST

**Guarantor of the article:** Lauren B. Gerson, MD, MSc, FACG.

**Specific author contributions:** All authors were involved in writing the manuscript and providing critical revision of the manuscript for important intellectual content.

**Financial support:** Leighton: Pfizer; Fidler: Beekley Medical; Cave: Capsovision and Olympus Tokyo.

**Potential competing interests:** Gerson has served as a consultant to Capsovision, Intramedic, Covidien, Given Imaging, and Fujinon. Leighton has served as a consultant to Olympus, Fujinon, Covidien, and Given Imaging. Cave has served as a consultant to Olympus Tokyo and Covidien.

#### REFERENCES

- Lau WY, Fan ST, Wong SH *et al.* Preoperative and intraoperative localisation of gastrointestinal bleeding of obscure origin. *Gut* 1987;28:869-77.
- Longstreth GF. Epidemiology and outcome of patients hospitalized with acute lower gastrointestinal hemorrhage: a population-based study. *Am J Gastroenterol* 1997;92:419-24.
- Guyatt GH, Oxman AD, Vist GE *et al.* GRADE: an emerging consensus on rating quality of evidence and strength of recommendations. *BMJ* 2008;336:924-6.
- Pasha SF, Leighton JA, Das A *et al.* Double-balloon enteroscopy and capsule endoscopy have comparable diagnostic yield in small-bowel disease: a meta-analysis. *Clin Gastroenterol Hepatol* 2008;6:671-6.
- Mylonaki M, Fritscher-Ravens A, Swain P. Wireless capsule endoscopy: a comparison with push enteroscopy in patients with gastroscopy and colonoscopy negative gastrointestinal bleeding. *Gut* 2003;52:1122-6.
- Norton ID, Petersen BT, Sorbi D *et al.* Management and long-term prognosis of Dieulafoy lesion. *Gastrointest Endosc* 1999;50:762-7.
- Sone Y, Kumada T, Toyoda H *et al.* Endoscopic management and follow up of Dieulafoy lesion in the upper gastrointestinal tract. *Endoscopy* 2005;37:449-53.
- Romaozinho JM, Pontes JM, Lérias C *et al.* Dieulafoy's lesion: management and long-term outcome. *Endoscopy* 2004;36:416-20.
- Schmulewitz N, Baillie J. Dieulafoy lesions: a review of 6 years of experience at a tertiary referral center. *Am J Gastroenterol* 2001;96:1688-94.
- Mitsui K, Tanaka S, Yamamoto H *et al.* Role of double-balloon endoscopy in the diagnosis of small-bowel tumors: the first Japanese multicenter study. *Gastrointest Endosc* 2009;70:498-504.
- Cangemi DJ, Patel MK, Gomez V *et al.* Small bowel tumors discovered during double-balloon enteroscopy: analysis of a large prospectively collected single-center database. *J Clin Gastroenterol* 2013;47:769-72.
- Pennazio M, Santucci R, Rondonotti E *et al.* Outcome of patients with obscure gastrointestinal bleeding after capsule endoscopy: report of 100 consecutive cases. *Gastroenterology* 2004;126:643-53.
- Shinozaki S, Yamamoto H, Yano T *et al.* Long-term outcome of patients with obscure gastrointestinal bleeding investigated by double-balloon endoscopy. *Clin Gastroenterol Hepatol* 2010;8:151-8.
- Gerson LB, Batenic MA, Newsom SL *et al.* Long-term outcomes after double-balloon enteroscopy for obscure gastrointestinal bleeding. *Clin Gastroenterol Hepatol* 2009;7:664-9.
- Fix OK, Simon JT, Farraye FA *et al.* Obscure gastrointestinal hemorrhage from mesenteric varices diagnosed by video capsule endoscopy. *Dig Dis Sci* 2006;51:1169-74.
- Raju GS, Gerson L, Das A *et al.* American Gastroenterological Association (AGA) Institute technical review on obscure gastrointestinal bleeding. *Gastroenterology* 2007;133:1697-717.
- Mant MJ, Bain VG, Maguire CG *et al.* Prevalence of occult gastrointestinal bleeding in celiac disease. *Clin Gastroenterol Hepatol* 2006;4:451-4.
- Buchman AL, Wallin A. Videocapsule endoscopy renders obscure gastrointestinal bleeding no longer obscure. *J Clin Gastroenterol* 2003;37:303-6.
- Yamamoto H, Yano T, Kita H *et al.* New system of double-balloon enteroscopy for diagnosis and treatment of small intestinal disorders. *Gastroenterology* 2003;125:1556-57.
- Tsujikawa T, Saitoh Y, Andoh A *et al.* Novel single-balloon enteroscopy for diagnosis and treatment of the small intestine: preliminary experiences. *Endoscopy* 2008;40:11-15.
- Paulsen SR, Huprich JE, Hara AK. CT enterography: noninvasive evaluation of Crohn's disease and obscure gastrointestinal bleed. *Radiol Clin N Am* 2007;45:303-15.
- Zaman A, Katon RM. Push enteroscopy for obscure gastrointestinal bleeding yields a high incidence of proximal lesions within reach of a standard endoscope. *Gastrointest Endosc* 1998;47:372-6.
- Descamps C, Schmit A, Van Gossum A. "Missed" upper gastrointestinal tract lesions may explain "occult" bleeding. *Endoscopy* 1999;31:452-5.
- Tang SJ, Christodoulou D, Zanati S *et al.* Wireless capsule endoscopy for obscure gastrointestinal bleeding: a single-centre, one-year experience. *Canad J Gastroenterol* 2004;18:559-65.
- van Turenhout ST, Jacobs MA, van Weyenberg SJ *et al.* Diagnostic yield of capsule endoscopy in a tertiary hospital in patients with obscure gastrointestinal bleeding. *Gastrointest Liver Dis* 2010;19:141-5.
- Tee HP, Kaffes AJ. Non-small-bowel lesions encountered during double-balloon enteroscopy performed for obscure gastrointestinal bleeding. *World J Gastroenterol* 2010;16:1885-9.
- Fry LC, Bellutti M, Neumann H *et al.* Incidence of bleeding lesions within reach of conventional upper and lower endoscopes in patients undergoing double-balloon enteroscopy for obscure gastrointestinal bleeding. *Aliment Pharmacol Ther* 2009;29:342-9.
- Lorenceau-Savale C, Ben-Soussan E, Ramirez S *et al.* Outcome of patients with obscure gastrointestinal bleeding after negative capsule endoscopy: results of a one-year follow-up study. *Gastroenterol Clin Biol* 2010;34:606-11.
- Lara LF, Bloomfield RS, Pineau BC. The rate of lesions found within reach of esophagogastroduodenoscopy during push enteroscopy depends on the type of obscure gastrointestinal bleeding. *Endoscopy* 2005;37:745-50.
- Robinson CA, Jackson C, Condon D *et al.* Impact of inpatient status and gender on small-bowel capsule endoscopy findings. *Gastrointest Endosc* 2011;74:1061-6.
- Vlachogiannakos J, Papaxoinis K, Viazis N *et al.* Bleeding lesions within reach of conventional endoscopy in capsule endoscopy examinations for obscure gastrointestinal bleeding: is repeating endoscopy economically feasible? *Dig Dis Sci* 2011;56:1763-8.
- Barkin JS, Schonfeld W, Thomsen S *et al.* Enteroscopy and small bowel biopsy—an improved technique for the diagnosis of small bowel disease. *Gastrointest Endosc* 1985;31:215-7.
- Foutch PG, Sawyer R, Sanowski RA. Push-enteroscopy for diagnosis of patients with gastrointestinal bleeding of obscure origin. *Gastrointest Endosc* 1990;36:337-41.
- Harewood GC, Gostout CJ, Farrell MA *et al.* Prospective controlled assessment of variable stiffness enteroscopy. *Gastrointest Endosc* 2003;58:267-71.
- Chak A, Koehler MK, Sundaram SN *et al.* Diagnostic and therapeutic impact of push enteroscopy: analysis of factors associated with positive findings. *Gastrointest Endosc* 1998;47:18-22.
- Chak A, Cooper GS, Canto MI *et al.* Enteroscopy for the initial evaluation of iron deficiency. *Gastrointest Endosc* 1998;47:144-8.
- Lin S, Branch MS, Shetzline M. The importance of indication in the diagnostic value of push enteroscopy. *Endoscopy* 2003;35:315-21.
- Hayat M, Axon AT, O'Mahony S. Diagnostic yield and effect on clinical outcomes of push enteroscopy in suspected small-bowel bleeding. *Endoscopy* 2000;32:369-72.
- Linder J, Cheruvattath R, Truss C *et al.* Diagnostic yield and clinical implications of push enteroscopy: results from a nonspecialized center. *J Clin Gastroenterol* 2002;35:383-6.
- Shimizu S, Tada M, Kawai K. Development of a new insertion technique in push-type enteroscopy. *Am J Gastroenterol* 1987;82:844-7.
- Taylor AC, Chen RY, Desmond PV. Use of an overtube for enteroscopy—does it increase depth of insertion? A prospective study of enteroscopy with and without an overtube. *Endoscopy* 2001;33:227-30.



42. Rondonotti E, Villa F, Mulder CJ *et al*. Small bowel capsule endoscopy in 2007: indications, risks and limitations. *World J Gastroenterol* 2007;13:6140-9.
43. Delvaux M, Fassler I, Gay G. Clinical usefulness of the endoscopic video capsule as the initial intestinal investigation in patients with obscure digestive bleeding: validation of a diagnostic strategy based on the patient outcome after 12 months. *Endoscopy* 2004;36:1067-73.
44. Ben Soussan E, Antonietti M, Herve S *et al*. Diagnostic yield and therapeutic implications of capsule endoscopy in obscure gastrointestinal bleeding. *Gastroenterol Clin Biol* 2004;28:1068-73.
45. Estevez E, Gonzalez-Conde B, Vazquez-Iglesias JL *et al*. Diagnostic yield and clinical outcomes after capsule endoscopy in 100 consecutive patients with obscure gastrointestinal bleeding. *Eur J Gastroenterol Hepatol* 2006;18:881-8.
46. Lai LH, Wong GL, Chow DK *et al*. Long-term follow-up of patients with obscure gastrointestinal bleeding after negative capsule endoscopy. *Am J Gastroenterol* 2006;101:1224-8.
47. Koh SJ, Im JP, Kim JW *et al*. Long-term outcome in patients with obscure gastrointestinal bleeding after negative capsule endoscopy. *World J Gastroenterol* 2013;19:1632-8.
48. Kim JB, Ye BD, Song Y *et al*. Frequency of rebleeding events in obscure gastrointestinal bleeding with negative capsule endoscopy. *J Gastroenterol Hepatol* 2013;28:834-40.
49. Bresci G, Parisi G, Bertoni M *et al*. The role of video capsule endoscopy for evaluating obscure gastrointestinal bleeding: usefulness of early use. *J Gastroenterol* 2005;40:256-9.
50. Carey EJ, Leighton JA, Heigh RI *et al*. A single-center experience of 260 consecutive patients undergoing capsule endoscopy for obscure gastrointestinal bleeding. *Am J Gastroenterol* 2007;102:89-95.
51. May A, Nachbar L, Ell C. Double-balloon enteroscopy (push-and-pull enteroscopy) of the small bowel: feasibility and diagnostic and therapeutic yield in patients with suspected small bowel disease. *Gastrointest Endosc* 2005;62:62-70.
52. Mishkin DS, Chuttani R, Croffie J *et al*. ASGE Technology Status Evaluation Report: wireless capsule endoscopy. *Gastrointest Endosc* 2006;63:539-45.
53. Goenka MK, Majumder S, Kumar S *et al*. Single center experience of capsule endoscopy in patients with obscure gastrointestinal bleeding. *World J Gastroenterol* 2011;17:774-8.
54. Singh A, Marshall C, Chaudhuri B *et al*. Timing of video capsule endoscopy relative to overt obscure GI bleeding: implications from a retrospective study. *Gastrointest Endosc* 2013;77:761-6.
55. Yamada A, Watabe H, Kobayashi Y *et al*. Timing of capsule endoscopy influences the diagnosis and outcome in obscure-overt gastrointestinal bleeding. *Hepato-gastroenterology* 2012;59:676-9.
56. Lepieur L, Dray X, Antonietti M *et al*. Factors associated with diagnosis of obscure gastrointestinal bleeding by video capsule endoscopy. *Clin Gastroenterol Hepatol* 2012;10:1376-80.
57. Lecleire S, Iwanicki-Caron I, Di-Fiore A *et al*. Yield and impact of emergency capsule endoscopy in severe obscure-overt gastrointestinal bleeding. *Endoscopy* 2012;44:337-42.
58. Goldstein JL, Eisen GM, Lewis B *et al*. Video capsule endoscopy to prospectively assess small bowel injury with celecoxib, naproxen plus omeprazole, and placebo. *Clin Gastroenterol Hepatol* 2005;3:133-41.
59. Lewis BS, Eisen GM, Friedman S. A pooled analysis to evaluate results of capsule endoscopy trials. *Endoscopy* 2005;37:960-5.
60. Appleyard M, Fireman Z, Glukhovskiy A *et al*. A randomized trial comparing wireless capsule endoscopy with push enteroscopy for the detection of small-bowel lesions. *Gastroenterology* 2000;119:1431-8.
61. Kong H, Kim YS, Hyun JJ *et al*. Limited ability of capsule endoscopy to detect normally positioned duodenal papilla. *Gastrointest Endosc* 2006;64:538-41.
62. Clarke JO, Giday SA, Magno P *et al*. How good is capsule endoscopy for detection of periampullary lesions? Results of a tertiary-referral center. *Gastrointest Endosc* 2008;68:267-72.
63. Karagiannis S, Ducker C, Dautel P *et al*. Identification of the duodenal papilla by colon capsule endoscope. *Z Gastroenterol* 2010;48:753-5.
64. Postgate A, Despott E, Burling D *et al*. Significant small-bowel lesions detected by alternative diagnostic modalities after negative capsule endoscopy. *Gastrointest Endosc* 2008;68:1209-14.
65. Arakawa D, Ohmiya N, Nakamura M *et al*. Outcome after enteroscopy for patients with obscure GI bleeding: diagnostic comparison between double-balloon endoscopy and videocapsule endoscopy. *Gastrointest Endosc* 2009;69:866-74.
66. Bar-Meir S. Video capsule endoscopy or double-balloon enteroscopy: are they equivalent? *Gastrointest Endosc* 2009;69:875-6.
67. Zagorowicz ES, Pietrzak AM, Wronska E *et al*. Small bowel tumors detected and missed during capsule endoscopy: single center experience. *World J Gastroenterol* 2013;19:9043-8.
68. Svarta S, Segal B, Law J *et al*. Diagnostic yield of repeat capsule endoscopy and the effect on subsequent patient management. *Canad J Gastroenterol* 2010;24:441-4.
69. Jones BH, Fleischer DE, Sharma VK *et al*. Yield of repeat wireless video capsule endoscopy in patients with obscure gastrointestinal bleeding. *Am J Gastroenterol* 2005;100:1058-64.
70. Min BH, Chang DK, Kim BJ *et al*. Does back-to-back capsule endoscopy increase the diagnostic yield over a single examination in patients with obscure gastrointestinal bleeding? *Gut Liver* 2010;4:54-9.
71. Viazis N, Papaxoinis K, Vlachogiannakos J *et al*. Is there a role for second-look capsule endoscopy in patients with obscure GI bleeding after a nondiagnostic first test? *Gastrointest Endosc* 2009;69:850-6.
72. Lewis BS, Swain P. Capsule endoscopy in the evaluation of patients with suspected small intestinal bleeding: results of a pilot study. *Gastrointest Endosc* 2002;56:349-53.
73. Pennazio M. Capsule endoscopy: where are we after 6 years of clinical use? *Dig Liver Dis* 2006;38:867-78.
74. Fry LC, De Petris G, Swain JM *et al*. Impaction and fracture of a video capsule in the small bowel requiring laparotomy for removal of the capsule fragments. *Endoscopy* 2005;37:674-6.
75. Cheifetz AS, Kornbluth AA, Legnani P *et al*. The risk of retention of the capsule endoscope in patients with known or suspected Crohn's disease. *Am J Gastroenterol* 2006;101:2218-22.
76. Sachdev MS, Leighton JA, Fleischer DE *et al*. A prospective study of the utility of abdominal radiographs after capsule endoscopy for the diagnosis of capsule retention. *Gastrointest Endosc* 2007;66:894-900.
77. Repici A, Barbon V, De Angelis C *et al*. Acute small-bowel perforation secondary to capsule endoscopy. *Gastrointest Endosc* 2008;67:180-3.
78. Monkemuller K, Fry LC, Bellutti M *et al*. Balloon-assisted enteroscopy: unifying double-balloon and single-balloon enteroscopy. *Endoscopy* 2008;40:537-39.
79. Sidhu R, Sanders DS. Double-balloon enteroscopy in the elderly with obscure gastrointestinal bleeding: safety and feasibility. *Eur J Gastroenterol Hepatol* 2013;25:1230-4.
80. Urs AN, Martinelli M, Rao P *et al*. Diagnostic and therapeutic utility of double-balloon enteroscopy in children. *J Pediatr Gastroenterol Nutr* 2014;58:204-12.
81. Yamamoto H, Sekine Y, Sato Y *et al*. Total enteroscopy with a nonsurgical steerable double-balloon method. *Gastrointest Endosc* 2001;53:216-20.
82. Mehdizadeh S, Ross A, Gerson L *et al*. What is the learning curve associated with double-balloon enteroscopy? Technical details and early experience in 6 U.S. tertiary care centers. *Gastrointest Endosc* 2006;64:740-50.
83. Nakamura M, Niwa Y, Ohmiya N *et al*. Preliminary comparison of capsule endoscopy and double-balloon enteroscopy in patients with suspected small-bowel bleeding. *Endoscopy* 2006;38:59-66.
84. Heine GD, Hadithi M, Groenen MJ *et al*. Double-balloon enteroscopy: indications, diagnostic yield, and complications in a series of 275 patients with suspected small-bowel disease. *Endoscopy* 2006;38:42-8.
85. May A, Nachbar L, Schneider M *et al*. Prospective comparison of push enteroscopy and push-and-pull enteroscopy in patients with suspected small-bowel bleeding. *Am J Gastroenterol* 2006;101:2016-24.
86. Lo SK, Mehdizadeh S. Therapeutic uses of double-balloon enteroscopy. *Gastrointest Endosc Clin N Am* 2006;16:363-76.
87. Yamamoto H, Kita H, Sunada K *et al*. Clinical outcomes of double-balloon enteroscopy for the diagnosis and treatment of small-intestinal diseases. *Clin Gastroenterol Hepatol* 2004;2:1010-6.
88. Gross SA, Stark ME. Initial experience with double-balloon enteroscopy at a U.S. center. *Gastrointest Endosc* 2008;67:890-7.
89. Zhang Q, He Q, Liu J *et al*. Combined use of capsule endoscopy and double-balloon enteroscopy in the diagnosis of obscure gastrointestinal bleeding: meta-analysis and pooled analysis. *Hepatogastroenterology* 2013;60:1885-91.
90. Monkemuller K, Neumann H, Meyer F *et al*. A retrospective analysis of emergency double-balloon enteroscopy for small-bowel bleeding. *Endoscopy* 2009;41:715-7.
91. Aniwan S, Viriyatsahakul V, Rerknimitr R *et al*. Urgent double balloon endoscopy provides higher yields than non-urgent double balloon endoscopy in overt obscure gastrointestinal bleeding. *Endosc Int Open* 2014;02:E90-5.

92. Byeon JS, Mann NK, Jamil LH *et al.* Is a repeat double balloon endoscopy in the same direction useful in patients with recurrent obscure gastrointestinal bleeding? *J Clin Gastroenterol* 2013;47:496–500.
93. Ell C, May A. Mid-gastrointestinal bleeding: capsule endoscopy and push-and-pull enteroscopy give rise to a new medical term. *Endoscopy* 2006;38:73–5.
94. May A, Farber M, Aschmoneit I *et al.* Prospective multicenter trial comparing push-and-pull enteroscopy with the single- and double-balloon techniques in patients with small-bowel disorders. *Am J Gastroenterol* 2010;105:575–81.
95. Mensink PB, Haringsma J, Kucharzik T *et al.* Complications of double balloon endoscopy: a multicenter survey. *Endoscopy* 2007;39:613–5.
96. Gerson LB, Flodin JT, Miyabayashi K. Balloon-assisted enteroscopy: technology and troubleshooting. *Gastrointest Endosc* 2008;68:1158–67.
97. May A, Nachbar L, Pohl J *et al.* Endoscopic interventions in the small bowel using double balloon enteroscopy: feasibility and limitations. *Am J Gastroenterol* 2007;102:527–35.
98. Domagk D, Bretthauer M, Lenz P *et al.* Carbon dioxide insufflation improves intubation depth in double-balloon enteroscopy: a randomized, controlled, double-blind trial. *Endoscopy* 2007;39:1064–7.
99. Dellon ES, Hawk JS, Grimm IS *et al.* The use of carbon dioxide for insufflation during GI endoscopy: a systematic review. *Gastrointest Endosc* 2009;69:843–9.
100. Moschler O, May A, Muller MK *et al.* Complications in and performance of double-balloon enteroscopy (DBE): results from a large prospective DBE database in Germany. *Endoscopy* 2011;43:484–9.
101. Vargo JJ, Upchurch BR, Dumot JA *et al.* Clinical utility of the Olympus single balloon enteroscope: the initial U.S. experience. *Gastrointest Endosc* 2007;65:AB90.
102. Prachayakul V, Deesomsak M, Aswakul P *et al.* The utility of single-balloon enteroscopy for the diagnosis and management of small bowel disorders according to their clinical manifestations: a retrospective review. *BMC Gastroenterol* 2013;13:103.
103. Zhu M, Zhang J, Tang J *et al.* Diagnostic value of single balloon endoscopy in obscure gastrointestinal bleeding. *World Chin J Digestol* 2014, 1033–6.
104. Manno M, Riccioni ME, Cannizzaro R *et al.* Diagnostic and therapeutic yield of single balloon enteroscopy in patients with suspected small-bowel disease: results of the Italian multicentre study. *Dig Liver Dis* 2013;45:211–5.
105. Kushnir VM, Tang M, Goodwin J *et al.* Long-term outcomes after single-balloon enteroscopy in patients with obscure gastrointestinal bleeding. *Dig Dis Sci* 2013;58:2572–9.
106. Aktas H, de Ridder L, Haringsma J *et al.* Complications of single-balloon enteroscopy: a prospective evaluation of 166 procedures. *Endoscopy* 2010;42:365–8.
107. Takano N, Yamada A, Watabe H *et al.* Single-balloon versus double-balloon endoscopy for achieving total enteroscopy: a randomized, controlled trial. *Gastrointest Endosc* 2011;73:734–9.
108. Domagk D, Mensink P, Aktas H *et al.* Single- vs. double-balloon enteroscopy in small-bowel diagnostics: a randomized multicenter trial. *Endoscopy* 2011;43:472–6.
109. Akerman PA, Agrawal D, Cantero D *et al.* Spiral enteroscopy with the new DSB overtube: a novel technique for deep peroral small-bowel intubation. *Endoscopy* 2008;40:974–8.
110. Ell C, May A, Nachbar L *et al.* Push-and-pull enteroscopy in the small bowel using the double-balloon technique: results of a prospective European multicenter study. *Endoscopy* 2005;37:613–6.
111. Di Caro S, May A, Heine DG *et al.* The European experience with double-balloon enteroscopy: indications, methodology, safety, and clinical impact. *Gastrointest Endosc* 2005;62:545–50.
112. Monkemuller K, Weigt J, Treiber G *et al.* Diagnostic and therapeutic impact of double-balloon enteroscopy. *Endoscopy* 2006;38:67–72.
113. Manabe N, Tanaka S, Fukumoto A *et al.* Double-balloon enteroscopy in patients with GI bleeding of obscure origin. *Gastrointest Endosc* 2006;64:135–40.
114. Akahoshi K, Kubokawa M, Matsumoto M *et al.* Double-balloon endoscopy in the diagnosis and management of GI tract diseases: Methodology, indications, safety, and clinical impact. *World J Gastroenterol* 2006;12:7654–9.
115. Kawamura T, Yasuda K, Tanaka K *et al.* Clinical evaluation of a newly developed single-balloon enteroscope. *Gastrointest Endosc* 2008;68:1112–6.
116. Ramchandani M, Reddy DN, Gupta R *et al.* Diagnostic yield and therapeutic impact of single-balloon enteroscopy: series of 106 cases. *J Gastroenterol Hepatol* 2009;24:1631–8.
117. Upchurch BR, Sanaka MR, Lopez AR *et al.* The clinical utility of single-balloon enteroscopy: a single-center experience of 172 procedures. *Gastrointest Endosc* 2010;71:1218–23.
118. Akerman PA, Cantero D. Severe complications of spiral enteroscopy in the first 1750 patients. *Gastrointest Endosc* 2009;69:5.
119. Buscaglia JM, Richards R, Wilkinson MN *et al.* Diagnostic yield of spiral enteroscopy when performed for the evaluation of abnormal capsule endoscopy findings. *J Clin Gastroenterol* 2011;45:342–6.
120. Judah JR, Draganov PV, Lam Y *et al.* Spiral enteroscopy is safe and effective for an elderly United States population of patients with numerous comorbidities. *Clin Gastroenterol Hepatol* 2010;8:572–6.
121. Despott EJ, Hughes S, Marden P *et al.* First cases of spiral enteroscopy in the UK: let's "torque" about it!. *Endoscopy* 2010;42:517.
122. Schembre DB, Ross AS. Spiral enteroscopy: a new twist on overtube-assisted endoscopy. *Gastrointest Endosc* 2009;69:333–6.
123. Williamson JB, Judah JR, Gaidos JK *et al.* Prospective evaluation of the long-term outcomes after deep small-bowel spiral enteroscopy in patients with obscure GI bleeding. *Gastrointest Endosc* 2012;76:771–8.
124. Akerman PA, Haniff M. Spiral enteroscopy: prime time or for the happy few? Best practice & research. *Clin Gastroenterol* 2012;26:293–301.
125. Jakobs R, Hartmann D, Benz C *et al.* Diagnosis of obscure gastrointestinal bleeding by intra-operative enteroscopy in 81 consecutive patients. *World J Gastroenterol* 2006;12:313–6.
126. Douard R, Wind P, Panis Y *et al.* Intraoperative enteroscopy for diagnosis and management of unexplained gastrointestinal bleeding. *Am J Surg* 2000;180:181–4.
127. Zaman A, Sheppard B, Katon RM. Total peroral intraoperative enteroscopy for obscure GI bleeding using a dedicated push enteroscope: diagnostic yield and patient outcome. *Gastrointest Endosc* 1999;50:506–10.
128. Lopez MJ, Cooley JS, Petros JG *et al.* Complete intraoperative small-bowel endoscopy in the evaluation of occult gastrointestinal bleeding using the sonde enteroscope. *Arch Surg* 1996;131:272–7.
129. Cave DR, Cooley JS. Intraoperative enteroscopy. Indications and techniques. *Gastrointest Endosc Clin N Am* 1996;6:793–802.
130. Ress AM, Benacci JC, Sarr MG. Efficacy of intraoperative enteroscopy in diagnosis and prevention of recurrent, occult gastrointestinal bleeding. *Am J Surg* 1992;163:94–8.
131. Leighton JA, Goldstein J, Hirota W *et al.* Obscure gastrointestinal bleeding. *Gastrointest Endosc* 2003;58:650–5.
132. Triester SL, Leighton JA, Leontiadis GI *et al.* A meta-analysis of the yield of capsule endoscopy compared to other diagnostic modalities in patients with obscure gastrointestinal bleeding. *Am J Gastroenterol* 2005;100:2407–18.
133. Chen X, Ran ZH, Tong JL. A meta-analysis of the yield of capsule endoscopy compared to double-balloon enteroscopy in patients with small bowel diseases. *World J Gastroenterol* 2007;13:4372–8.
134. Teshima CW, Kuipers EJ, van Zanten SV *et al.* Double balloon enteroscopy and capsule endoscopy for obscure gastrointestinal bleeding: an updated meta-analysis. *J Gastroenterol Hepatol* 2011;26:796–801.
135. Wang BQ, Sun GB, Lou WH *et al.* Double balloon enteroscopy vs capsule endoscopy for obscure gastrointestinal bleeding: a meta-analysis. *World Chin J Digestol* 2013;21:4060–5.
136. Fry LC, Neumann H, Jovanovic I *et al.* Capsule endoscopy increases the diagnostic yield of double balloon enteroscopy in patients being investigated for obscure gastrointestinal bleeding. *Arch Gastroenterohepatol* 2012;29:9–14.
137. Gay G, Delvaux M, Fassler I. Outcome of capsule endoscopy in determining indication and route for push-and-pull enteroscopy. *Endoscopy* 2006;38:49–58.
138. Kaffes AJ, Siah C, Koo JH. Clinical outcomes after double-balloon enteroscopy in patients with obscure GI bleeding and a positive capsule endoscopy. *Gastrointest Endosc* 2007;66:304–9.
139. Hendel JW, Vilmann P, Jensen T. Double-balloon endoscopy: Who needs it? *Scand J Gastroenterol* 2008;43:363–7.
140. Ross A, Mehdizadeh S, Tokar J *et al.* Double balloon enteroscopy detects small bowel mass lesions missed by capsule endoscopy. *Dig Dis Sci* 2008;53:2140–3.
141. May A, Manner H, Aschmoneit I *et al.* Prospective, cross-over, single-center trial comparing oral double-balloon enteroscopy and oral spiral enteroscopy in patients with suspected small-bowel vascular malformations. *Endoscopy* 2011;43:477–83.
142. Rahmi G, Samaha E, Vahedi K *et al.* Multicenter comparison of double-balloon enteroscopy and spiral enteroscopy. *J Gastroenterol Hepatol* 2013;28:992–8.

143. Gerson L, Kamal A. Cost-effectiveness analysis of management strategies for obscure GI bleeding. *Gastrointest Endosc* 2008;68:920–36.
144. Leighton JA, Triester SL, Sharma VK. Capsule endoscopy: a meta-analysis for use with obscure gastrointestinal bleeding and Crohn's disease. *Gastrointest Endosc Clin N Am* 2006;16:229–50.
145. Nutter M, Dunston D, Ieyoub J *et al*. A retrospective analysis comparing small bowel follow-through with wireless capsule endoscopy in the evaluation of obscure gastrointestinal bleeding. *Gastroenterol Nurs* 2010;33:298–302.
146. Rajesh A, Sandrasegaran K, Jennings SG *et al*. Comparison of capsule endoscopy with enteroclysis in the investigation of small bowel disease. *Abdom Imaging* 2009;34:459–66.
147. Hara AK, Leighton JA, Sharma VK *et al*. Small bowel: preliminary comparison of capsule endoscopy with barium study and CT. *Radiology* 2004;230:260–5.
148. Giuffre P, Montalbano C. Comparative evaluation between capsule endoscopy and CT enteroclysis in the study of obscure gastrointestinal bleedings: our experience. *Acta Med Mediterr* 2013;29:467–73.
149. Golder SK, Schreyer AG, Endlicher E *et al*. Comparison of capsule endoscopy and magnetic resonance (MR) enteroclysis in suspected small bowel disease. *Int J Colorectal Dis* 2006;21:97–104.
150. Wiarda BM, Heine DG, Mensink P *et al*. Comparison of magnetic resonance enteroclysis and capsule endoscopy with balloon-assisted enteroscopy in patients with obscure gastrointestinal bleeding. *Endoscopy* 2012;44:668–73.
151. Agrawal JR, Travis AC, Morteale KJ *et al*. Diagnostic yield of dual-phase computed tomography enterography in patients with obscure gastrointestinal bleeding and a non-diagnostic capsule endoscopy. *J Gastroenterol Hepatol* 2012;27:751–9.
152. Hara AK, Walker FB, Silva AC *et al*. Preliminary estimate of triphasic CT enterography performance in hemodynamically stable patients with suspected gastrointestinal bleeding. *Am J Roentgenol* 2009;193:1252–60.
153. Huprich JE, Fletcher JG, Alexander JA *et al*. Obscure gastrointestinal bleeding: evaluation with 64-section multiphase CT enterography—initial experience. *Radiology* 2008;246:562–71.
154. Huprich JE, Fletcher JG, Fidler JL *et al*. Prospective blinded comparison of wireless capsule endoscopy and multiphase CT enterography in obscure gastrointestinal bleeding. *Radiology* 2011;260:744–51.
155. Kulkarni C, Moorthy S, Sreekumar K *et al*. In the workup of patients with obscure gastrointestinal bleed, does 64-slice MDCT have a role? *Indian J Radiol Imag* 2012;22:47–53.
156. Lee SS, Oh TS, Kim HJ *et al*. Obscure gastrointestinal bleeding: diagnostic performance of multidetector CT enterography. *Radiology* 2011;259:739–48.
157. Jain TP, Gulati MS, Makharia GK *et al*. CT enteroclysis in the diagnosis of obscure gastrointestinal bleeding: initial results. *Clin Radiol* 2007;62:660–7.
158. Eid M, El Sirafy MN, Kassem MI. Role of CT enterography in obscure gastrointestinal bleeding. *Egypt J Radiol Nucl Med* 2013;44:9–14.
159. Sodhi JS, Zargar SA, Rashid W *et al*. 64-Section multiphase CT enterography as a diagnostic tool in the evaluation of obscure gastrointestinal bleeding. *Indian J Gastroenterol* 2012;31:61–8.
160. Wang Z, Chen JQ, Liu JL *et al*. CT enterography in obscure gastrointestinal bleeding: a systematic review and meta-analysis. *J Med Imag Radiat Oncol* 2013;57:263–73.
161. Heo HM, Park CH, Lim JS *et al*. The role of capsule endoscopy after negative CT enterography in patients with obscure gastrointestinal bleeding. *Eur Radiol* 2012;22:1159–66.
162. Bocker U, Dinter D, Litterer C *et al*. Comparison of magnetic resonance imaging and video capsule enteroscopy in diagnosing small-bowel pathology: localization-dependent diagnostic yield. *Scand J Gastroenterol* 2010;45:490–500.
163. Khalife S, Soyer P, Alatawi A *et al*. Obscure gastrointestinal bleeding: preliminary comparison of 64-section CT enteroclysis with video capsule endoscopy. *Eur Radiol* 2011;21:79–86.
164. Wu LM, Xu JR, Yin Y *et al*. Usefulness of CT angiography in diagnosing acute gastrointestinal bleeding: a meta-analysis. *World J Gastroenterol* 2010;16:3957–63.
165. Yoon W, Jeong YY, Shin SS *et al*. Acute massive gastrointestinal bleeding: detection and localization with arterial phase multi-detector row helical CT. *Radiology* 2006;239:160–7.
166. Kennedy DW, Laing CJ, Tseng LH *et al*. Detection of active gastrointestinal hemorrhage with CT angiography: a 4(1/2)-year retrospective review. *J Vasc Interv Radiol* 2010;21:848–55.
167. Palma J, Mihaila M, Pilleul F. Multidetector computed tomography in acute lower gastrointestinal bleeding. *Rep Med Imag* 2010;3:107–13.
168. Sun H, Jin Z, Li X *et al*. Detection and localization of active gastrointestinal bleeding with multidetector row computed tomography angiography: a 5-year prospective study in one medical center. *J Clin Gastroenterol* 2012;46:31–41.
169. Yen HH, Chen YY, Yang CW *et al*. Clinical impact of multidetector computed tomography before double-balloon enteroscopy for obscure gastrointestinal bleeding. *World J Gastroenterol* 2012;18:692–7.
170. Tan KK, Shore T, Strong DH *et al*. Factors predictive for a positive invasive mesenteric angiogram following a positive CT angiogram in patients with acute lower gastrointestinal haemorrhage. *Int J Colorectal Dis* 2013;28:1715–9.
171. Howarth DM, Tang K, Lees W. The clinical utility of nuclear medicine imaging for the detection of occult gastrointestinal haemorrhage. *Nucl Med Commun* 2002;23:591–4.
172. Howarth DM. The role of nuclear medicine in the detection of acute gastrointestinal bleeding. *Semin Nucl Med* 2006;36:133–46.
173. Aksoy T. Obscure and occult gastrointestinal bleeding: role of radionuclide imaging. *Abdom Imag* 2012.
174. Asghar AH, Khan A, Khan AA *et al*. Role of Tc-99m labeled RBC scan in evaluation of gastrointestinal bleed. *J Coll Phys Surg Pak* 2002;12:335–7.
175. Brunner T, Klebl F, Mundorff S *et al*. Significance of scintigraphy for the localisation of obscure gastrointestinal bleedings. *World J Gastroenterol* 2008;14:5015–9.
176. Dolezal J, Vizda J, Bures J. Detection of acute gastrointestinal bleeding by means of technetium-99m *in vivo* labelled red blood cells. *Nat Med Central Eastern Eur* 2002;5:151–4.
177. Dolezal J, Vizda J, Kopacova M. Single-photon emission computed tomography enhanced Tc-99m-pertechnetate disodium-labelled red blood cell scintigraphy in the localization of small intestine bleeding: a single-centre twelve-year study. *Digestion* 2011;84:207–11.
178. Dusold R, Burke K, Carpentier W *et al*. The accuracy of technetium-99m-labeled red cell scintigraphy in localizing gastrointestinal bleeding. *Am J Gastroenterol* 1994;89:345–8.
179. Friebe B, Wieners G. Radiographic techniques for the localization and treatment of gastrointestinal bleeding of obscure origin. *Eur J Trauma Emerg Surg* 2011;37:353–63.
180. Rajnish A, Sudhakar P, Rammurti S *et al*. Scintigraphic localization of lower gastrointestinal haemorrhage of obscure origin. *Asian Ocean J Radiol* 2000;5:217–20.
181. Rollins ES, Picus D, Hicks ME *et al*. Angiography is useful in detecting the source of chronic gastrointestinal bleeding of obscure origin. *Am J Roentgenol* 1991;156:385–8.
182. Charbonnet P, Toman J, Buhler L *et al*. Treatment of gastrointestinal hemorrhage. *Abdom Imag* 2005;30:719–26.
183. Strate LL, Syngal S. Predictors of utilization of early colonoscopy vs. radiography for severe lower intestinal bleeding. *Gastrointest Endosc* 2005;61:46–52.
184. Kong MS, Huang SC, Tzen KY *et al*. Repeated technetium-99m pertechnetate scanning for children with obscure gastrointestinal bleeding. *J Pediatr Gastroenterol Nutr* 1994;18:284–7.
185. Spottswood SE, Pfluger T, Bartold SP *et al*. SNMMI and EANM practice guideline for meckel diverticulum scintigraphy 2.0. *J Nucl Med Technol* 2014;42:163–9.
186. Al Janabi M, Samuel M, Kahlenberg A *et al*. Symptomatic paediatric Meckel's diverticulum: stratified diagnostic indicators and accuracy of Meckel's scan. *Nucl Med Commun* 2014;35:1162–6.
187. Uppal K, Tubbs RS, Matusz P *et al*. Meckel's diverticulum: a review. *Clin Anat* 2011;24:416–22.
188. Strate LL. Lower GI. bleeding: epidemiology and diagnosis. *Gastroenterol Clin N Am* 2005;34:643–64.
189. Leung WK, Ho SS, Suen BY *et al*. Capsule endoscopy or angiography in patients with acute overt obscure gastrointestinal bleeding: a prospective randomized study with long-term follow-up. *Am J Gastroenterol* 2012;107:1370–6.
190. Gillespie CJ, Sutherland AD, Mossop PJ *et al*. Mesenteric embolization for lower gastrointestinal bleeding. *Dis Colon Rectum* 2010;53:1258–64.
191. Abbas SM, Bissett IP, Holden A *et al*. Clinical variables associated with positive angiographic localization of lower gastrointestinal bleeding. *ANZ J Surg* 2005;75:953–7.
192. Whitaker SC, Gregson RHS. The role of angiography in the investigation of acute or chronic gastrointestinal haemorrhage. *Clin Radiol* 1993;47:382–8.

193. Kim CY, Suhocki PV, Miller MJ Jr *et al.* Provocative mesenteric angiography for lower gastrointestinal hemorrhage: results from a single-institution study. *J Vasc Interv Radiol* 2010;21:477–83.
194. Weldon DT, Burke SJ, Sun S *et al.* Interventional management of lower gastrointestinal bleeding. *Eur Radiol* 2008;18:857–67.
195. Hongsakul K, Pakdeejit S, Tanutit P. Outcome and predictive factors of successful transarterial embolization for the treatment of acute gastrointestinal hemorrhage. *Acta Radiol* 2014;55:186–94.
196. Richter JM, Christensen MR, Colditz GA *et al.* Angiodysplasia. Natural history and efficacy of therapeutic interventions. *Dig Dis Sci* 1989;34:1542–6.
197. Landi B, Cellier C, Gaudric M *et al.* Long-term outcome of patients with gastrointestinal bleeding of obscure origin explored by push endoscopy. *Endoscopy* 2002;34:355–9.
198. Saurin JC, Delvaux M, Vahedi K *et al.* Clinical impact of capsule endoscopy compared to push enteroscopy: 1-year follow-up study. *Endoscopy* 2005;37:318–23.
199. Laine L, Sahota A, Shah A. Does capsule endoscopy improve outcomes in obscure gastrointestinal bleeding? Randomized trial versus dedicated small bowel radiography. *Gastroenterology* 2010;138:1673–80.
200. Junquera F, Feu F, Papo M *et al.* A multicenter, randomized, clinical trial of hormonal therapy in the prevention of rebleeding from gastrointestinal angiodysplasia. *Gastroenterology* 2001;121:1073–9.
201. Samaha E, Rahmi G, Landi B *et al.* Long-term outcome of patients treated with double balloon enteroscopy for small bowel vascular lesions. *Am J Gastroenterol* 2012;107:240–6.
202. Jackson CS, Gerson LB. Management of gastrointestinal angiodysplastic lesions (GIADs): a systematic review and meta-analysis. *Am J Gastroenterol* 2014;109:474–83.
203. Rutgeerts P, Van Gompel F, Geboes K *et al.* Long term results of treatment of vascular malformations of the gastrointestinal tract by neodymium Yag laser photocoagulation. *Gut* 1985;26:586–93.
204. Lepere C, Cuillierier E, Van Gossum A *et al.* Predictive factors of positive findings in patients explored by push endoscopy for unexplained GI bleeding. *Gastrointest Endosc* 2005;61:709–14.
205. Fan GW, Chen TH, Lin WP *et al.* Angiodysplasia and bleeding in the small intestine treated by balloon-assisted enteroscopy. *J Dig Dis* 2013;14:113–6.
206. Karagiannis S, Goulas S, Kosmadakis G *et al.* Wireless capsule endoscopy in the investigation of patients with chronic renal failure and obscure gastrointestinal bleeding (preliminary data). *World J Gastroenterol* 2006;12:5182–5.
207. Batur P, Stewart WJ, Isaacson JH. Increased prevalence of aortic stenosis in patients with arteriovenous malformations of the gastrointestinal tract in Heyde syndrome. *Arch Intern Med* 2003;163:1821–4.
208. Warkentin TE, Moore JC, Morgan DG. Aortic stenosis and bleeding gastrointestinal angiodysplasia: is acquired von Willebrand's disease the link? *Lancet* 1992;340:35–7.
209. Shrode CW, Draper KV, Huang RJ *et al.* Significantly higher rates of gastrointestinal bleeding and thromboembolic events with left ventricular assist devices. *Clin Gastroenterol Hepatol* 2014;12:1461–7.
210. Joyce D, Crow S, Li Z *et al.* Pilot investigation of a novel testing strategy for bleeding in ventricular assist device recipients. *J Heart Lung Transplant* 2012;31:750–6.
211. Goddard AF, James MW, McIntyre AS *et al.* Guidelines for the management of iron deficiency anaemia. *Gut* 2011;60:1309–16.
212. Shinozaki S, Yamamoto H, Yano T *et al.* Long-term outcome of patients with obscure gastrointestinal bleeding investigated by double-balloon endoscopy. *Clin Gastroenterol Hepatol* 2010;8:151–8.
213. Liu YK, Kosfeld RE, Marcum SG. Treatment of uraemic bleeding with conjugated oestrogen. *Lancet* 1984;2:887–90.
214. Koh KK, Mincemoyer R, Bui MN *et al.* Effects of hormone-replacement therapy on fibrinolysis in postmenopausal women. *N Engl J Med* 1997;336:683–90.
215. van Cutsem E, Rutgeerts P, Vantrappen G. Treatment of bleeding gastrointestinal vascular malformations with oestrogen-progesterone. *Lancet* 1990;335:953–5.
216. Nardone G, Rocco A, Balzano T *et al.* The efficacy of octreotide therapy in chronic bleeding due to vascular abnormalities of the gastrointestinal tract. *Aliment Pharmacol Ther* 1999;13:1429–36.
217. Lewis BS, Salomon P, Rivera-MacMurray S *et al.* Does hormonal therapy have any benefit for bleeding angiodysplasia? *J Clin Gastroenterol* 1992;15:99–103.
218. Szilagyi A, Ghali MP. Pharmacological therapy of vascular malformations of the gastrointestinal tract. *Can J Gastroenterol* 2006;20:171–8.
219. Brown C, Subramanian V, Wilcox CM *et al.* Somatostatin analogues in the treatment of recurrent bleeding from gastrointestinal vascular malformations: an overview and systematic review of prospective observational studies. *Dig Dis Sci* 2010;55:2129–34.
220. Bon C, Aparicio T, Vincent M *et al.* Long-acting somatostatin analogues decrease blood transfusion requirements in patients with refractory gastrointestinal bleeding associated with angiodysplasia. *Aliment Pharmacol Ther* 2012;36:587–93.
221. Nardone G, Compare D, Scarpignato C *et al.* Long acting release-octreotide as "rescue" therapy to control angiodysplasia bleeding: a retrospective study of 98 cases. *Dig Liver Dis* 2014;46:688–94.
222. Stephens TD, Bunde CJ, Fillmore BJ. Mechanism of action in thalidomide teratogenesis. *Biochem Pharmacol* 2000;59:1489–99.
223. Ge ZZ, Chen HM, Gao YJ *et al.* Efficacy of thalidomide for refractory gastrointestinal bleeding from vascular malformation. *Gastroenterology* 2011;141:1629–37.
224. Garrido A, Sayago M, Lopez J *et al.* Thalidomide in refractory bleeding due to gastrointestinal angiodysplasias. *Rev Esp Enferm Dig* 2012;104:69–71.
225. Milewski PJ, Schofield PF. Massive colonic haemorrhage—the case for right hemicolectomy. *Ann R Coll Surg Engl* 1989;71:253–9.
226. Hartmann D, Schmidt H, Bolz G *et al.* A prospective two-center study comparing wireless capsule endoscopy with intraoperative enteroscopy in patients with obscure GI bleeding. *Gastrointest Endosc* 2005;61:826–32.
227. Frydman J, Bahouth H, Leiderman M *et al.* Methylene Blue injection via superior mesenteric artery microcatheter for focused enterectomy in the treatment of a bleeding small intestinal arteriovenous malformation. *World J Emerg Surg* 2014;9:17.

## APPENDIX

### Literature Search

#### MEDLINE

(1) Hemorrhage, gastrointestinal/ or "gastrointestinal hemorrhage\*".mp. or "gastrointestinal haemorrhage\*".mp. or melena.mp. or hematoemisis.mp. or hematochez\*.mp. or haematochez\*.mp. [mp=title, abstract, original title, name of substance word, subject heading word, keyword heading word, protocol supplementary concept word, rare disease supplementary concept word, unique identifier]

(2) 1 and (obscure or ogib\*).mp. [mp=title, abstract, original title, name of substance word, subject heading word, keyword heading word, protocol supplementary concept word, rare disease supplementary concept word, unique identifier]

(3) 1 and overt.mp. and occult.mp. [mp=title, abstract, original title, name of substance word, subject heading word, keyword heading word, protocol supplementary concept word, rare disease supplementary concept word, unique identifier]

(4) 2 or 3

(5) exp intestine, small/bs, pa, ra, ri or exp duodenal diseases/pa, co, di, et, ra, ri, eh, ep or exp ileal diseases/pa, co, di, et, ra, ri, eh, ep or exp jejunal diseases/pa, co, di, et, ra, ri, eh, ep

- (6) 1 and 5
- (7) 6 and (obscure or occult or overt).mp. [mp=title, abstract, original title, name of substance word, subject heading word, keyword heading word, protocol supplementary concept word, rare disease supplementary concept word, unique identifier]
- (8) 4 or 7
- (9) anemia, iron deficiency/ or ida.tw. or localiz\*.mp. or localis\*.mp. or visuali\*.mp. or fobt.mp. or occult blood/ or "occult blood".mp. or missed.mp. or diagnostic errors/ or diagnosis, differential/ [mp=title, abstract, original title, name of substance word, subject heading word, keyword heading word, protocol supplementary concept word, rare disease supplementary concept word, unique identifier]
- (10) 6 and 9
- (11) 8 or 10
- (12) avms.mp. or meckels diverticulum/ or vascular diseases/ra, di, ri or dieulafoy\*.mp. or telangiectasia\*.mp. or ectasia\*.mp. or heman-gioma\*.mp. or haemangioma\*.mp. or angiodysplasi\*.mp. [mp=title, abstract, original title, name of substance word, subject heading word, keyword heading word, protocol supplementary concept word, rare disease supplementary concept word, unique identifier]
- (13) lvad\*.mp. or heart assist devices/ or "osler weber".mp. or "blue rubber".mp. or erosion\*.mp. or willebrand\*.mp. or crohn\*.mp. [mp=title, abstract, original title, name of substance word, subject heading word, keyword heading word, protocol supplementary concept word, rare disease supplementary concept word, unique identifier]
- (14) 6 and (12 or 13)
- (15) exp anticoagulants/ or exp fibrinolytic agents/ or exp platelet aggregation inhibitors/
- (16) (exp anticoagulants/ae or exp fibrinolytic agents/ae or exp platelet aggregation inhibitors/ae) and 6
- (17) 11 or 14 or 16
- (18).../ 17 lg=en and hu=y and yr=1980–2014
- (19) exp Gastrointestinal Hemorrhage/ci, cl, di, dh, dt, ec, ep, eh, et, mo, pa, pp, pc, ra, ri, rh, su, th, us [Chemically Induced, Classification, Diagnosis, Diet Therapy, Drug Therapy, Economics, Epidemiology, Ethnology, Etiology, Mortality, Pathology, Physiopathology, Prevention & Control, Radiography, Radionuclide Imaging, Rehabilitation, Surgery, Therapy, Ultrasonography]
- (20) 18 and 19
- (21) 18 and (esophagoduodenoscop\*.mp. or endoscopy/ or exp endoscopy, gastrointestinal/ or capsule endoscopy/ or dbe.mp. or "double balloon".mp. or enteroscop\*.mp. or duodenoscopy/ or esophagoscopy/ or gastroscopy/ or colonoscopy/) [mp=title, abstract, original title, name of substance word, subject heading word, keyword heading word, protocol supplementary concept word, rare disease supplementary concept word, unique identifier]
- (22). exp angiography/ or exp radiographic image enhancement/ or exp radiographic image interpretation, computer-assisted/ or exp radiography, abdominal/ or exp radionuclide imaging/ or exp tomography/
- (23) diagnostic imaging/ or exp magnetic resonance imaging/
- (24) "tagged red blood".mp. or erythrocytes/ri [mp=title, abstract, original title, name of substance word, subject heading word, keyword heading word, protocol supplementary concept word, rare disease supplementary concept word, unique identifier]
- (25) exp Radionuclide Imaging/
- (26) 18 and (22 or 23 or 24 or 25)
- (27) exp diagnostic imaging/ae, st, ut, ed
- (28) 18 and 27
- (29) 18 and (education\*.tw. or train\*.mp. or simulat\*.mp.) [mp=title, abstract, original title, name of substance word, subject heading word, keyword heading word, protocol supplementary concept word, rare disease supplementary concept word, unique identifier]
- (30) 18 and clinical competence/
- (31) 28 or 29 or 30
- (32) 20 or 26 or 28 or 31
- (33) 18 and manag\*.mp. [mp=title, abstract, original title, name of substance word, subject heading word, keyword heading word, protocol supplementary concept word, rare disease supplementary concept word, unique identifier]
- (34) 18 and (rebleed\* or recurr\* or yield\* or algorithm\* or repeat\*).mp. [mp=title, abstract, original title, name of substance word, subject heading word, keyword heading word, protocol supplementary concept word, rare disease supplementary concept word, unique identifier]
- (35) exp endoscopy/ed, st
- (36) 18 and 35
- (37) 31 or 36
- (38) 32 or 33 or 34 or 37
- (39) remove duplicates from 38
- (40) 39 and (longitudinal studies/ or follow-up studies/ or cohort\*.mp. or series.mp. or prospective\*.mp. or retrospective\*.mp.) [mp=title, abstract, original title, name of substance word, subject heading word, keyword heading word, protocol supplementary concept word, rare disease supplementary concept word, unique identifier]

(41) limit 39 to (clinical trial, all or clinical trial, phase i or clinical trial, phase ii or clinical trial, phase iii or clinical trial, phase iv or clinical trial or comparative study or controlled clinical trial or evaluation studies or meta analysis or multicenter study or observational study or pragmatic clinical trial or practice guideline or randomized controlled trial or "review" or systematic reviews or validation studies)

(42) exp case-control studies/ or exp cohort studies/ or exp cross-sectional studies/ or exp feasibility studies/ or exp intervention studies/ or exp pilot projects/

(43) 39 and 42

(44) 40 or 41 or 43

EMBASE(1) hemorrhage, gastrointestinal/ or "gastrointestinal hemorrhage\*".mp. or "gastrointestinal haemorrhage\*".mp. or melena.mp. or hematoemesis.mp. or hematochez\*.mp. or haematochez\*.mp. [mp=title, abstract, subject headings, heading word, drug trade name, original title, device manufacturer, drug manufacturer, device trade name, keyword]

(2) 1 and (obscure or ogib\*).mp. [mp=title, abstract, subject headings, heading word, drug trade name, original title, device manufacturer, drug manufacturer, device trade name, keyword]

(3) 1 and overt.mp. and occult.mp. [mp=title, abstract, subject headings, heading word, drug trade name, original title, device manufacturer, drug manufacturer, device trade name, keyword]

(4) 2 or 3

(5) anemia, iron deficiency/ or ida.tw. or localiz\*.mp. or localis\*.mp. or visuali\*.mp. or fobt.mp. or occult blood/ or "occult blood".mp. or missed.mp. or diagnostic errors/ or diagnosis, differential/ [mp=title, abstract, subject headings, heading word, drug trade name, original title, device manufacturer, drug manufacturer, device trade name, keyword]

(6) avms.mp. or meckels diverticulum/ or vascular diseases/ra, di, ri or dieulafoy\*.mp. or telangiectasia\*.mp. or ectasia\*.mp. or heman-gioma\*.mp. or haemangioma\*.mp. or angiodysplasi\*.mp. [mp=title, abstract, subject headings, heading word, drug trade name, original title, device manufacturer, drug manufacturer, device trade name, keyword]

(7) lvad\*.mp. or heart assist devices/ or "osler weber".mp. or "blue rubber".mp. or erosion\*.mp. or willebrand\*.mp. or crohn\*.mp. [mp=title, abstract, subject headings, heading word, drug trade name, original title, device manufacturer, drug manufacturer, device trade name, keyword]

(8) exp anticoagulants/ or exp fibrinolytic agents/ or exp platelet aggregation inhibitors/

(9) exp angiography/ or exp radiographic image enhancement/ or exp radiographic image interpretation, computer-assisted/ or exp radiography, abdominal/ or exp radionuclide imaging/ or exp tomography/

(10) diagnostic imaging/ or exp magnetic resonance imaging/

(11) "tagged red blood".mp. or erythrocytes/ri [mp=title, abstract, subject headings, heading word, drug trade name, original title, device manufacturer, drug manufacturer, device trade name, keyword]

(12) exp Radionuclide Imaging/

(13) exp case control study/ or exp case study/ or exp clinical trial/ or exp "clinical trial (topic)"/ or exp intervention study/ or exp longitudinal study/ or exp major clinical study/ or exp prospective study/ or exp retrospective study/

(14) or/5-12

(15) 1 and 14

(16) 15 and (obscure or ogib\* or occult or overt).mp. [mp=title, abstract, subject headings, heading word, drug trade name, original title, device manufacturer, drug manufacturer, device trade name, keyword]

(17) 4 or 16

(18) 13 and 17

(19) exp cohort analysis/ or exp correlational study/ or exp cross-sectional study/ or exp evidence based practice/ or exp practice guideline/

(20) 17 and 19

(21) 18 or 20

(22) remove duplicates from 21

(23) exp gastrointestinal hemorrhage/co, di, dm, ep, et, pc, si, su, th [Complication, Diagnosis, Disease Management, Epidemiology, Etiology, Prevention, Side Effect, Surgery, Therapy]

(24) 22 and 23

(25) exp diagnostic accuracy/ or exp diagnostic error/ or exp diagnostic reasoning/ or exp diagnostic test accuracy study/ or exp diagnostic value/ or exp differential diagnosis/ or exp endoscopy/

(26) 23 and 25

(27) 17 and 26

(28) (13 or 19) and 27

(29) 24 or 28

*SCOPUS*

(TITLE-ABS-KEY((obscure OR occult OR overt OR active OR suspect\* OR unknown OR acute) AND (gi OR gastrointestinal\* OR intestinal) AND (bleed\* OR rebleed\* OR hemorrhag\* OR haemorrhag\*) AND (ct OR tomogra\* OR enterography OR angiography OR mdct OR endoscop\* OR enteroscop\* OR imag\*)) ANDPUBYEAR>1979) AND (performance OR useful\* OR value OR important OR plan\* OR suggest\* OR diagnos\* OR accura\* OR missed) AND NOT (PMID(1\* OR 2\* OR 3\* OR 4\* OR 5\* OR 6\* OR 7\* OR 8\* OR 9\*)) AND (EXCLUDE(DOCTYPE, "ch") OR EXCLUDE(DOCTYPE, "ip") OR EXCLUDE(DOCTYPE, "sh") OR EXCLUDE(DOCTYPE, "no") OR EXCLUDE(DOCTYPE, "le") OR EXCLUDE(DOCTYPE, "bk")) AND (LIMIT-TO(LANGUAGE, "English")) 1150.